

## Asymmetric Mammographic Findings Based on the Fourth Edition of BI-RADS: Types, Evaluation, and Management<sup>1</sup>

Ji Hyun Youk, MD, Eun-Kyung Kim, MD, Kyung Hee Ko, MD, Min Jung Kim, MD

<sup>1</sup>From the Department of Diagnostic Radiology, Bundang CHA General Hospital, Pochon CHA University, Seongnam, South Korea (J.H.Y., K.H.K.); and the Department of Radiology, Research Institute of Radiological Science, Yonsei University College of Medicine, Seodaemun-ku, Shinchon-dong 134, Seoul, 120-752, Seoul, South Korea (E.K.K., M.J.K.). Presented as an education exhibit at the 2007 RSNA Annual Meeting. Received February 20, 2008; revision requested May 29; final revision received and accepted September 16. All authors have no financial relationships to disclose. **Address correspondence to E.K.K.** (e-mail: ekkim@yuhs.ac).

**Abbreviations:** BI-RADS = Breast Imaging Reporting and Data System, CC = craniocaudal, MLO = mediolateral oblique.

### Abstract

Asymmetric breast findings are frequently encountered at screening and diagnostic mammography. However, there has been some confusion about the applicable terminology for describing asymmetric breast findings. The fourth edition of the American College of Radiology Breast Imaging Reporting and Data System (BI-RADS) has incorporated changes in the lexicon for asymmetric breast findings to address such problems and improve the clinical utility of reporting. The fourth edition has replaced “asymmetric breast tissue” with “global asymmetry,” “density seen in only a single projection” with “asymmetry,” and “focal asymmetric density” with “focal asymmetry.” Once an asymmetric finding is perceived, it should be determined whether it is due to a definite lesion. To interpret and manage asymmetric breast findings, additional imaging studies such as straight lateral views, rolled views, and spot compression views at mammography and ultrasonography or magnetic resonance imaging should be applied appropriately in a logical work flow, and the radiologist should be aware of the pitfalls and pearls of each technique and modality.

---

### TEACHING POINTS

*See last page*

---

## Learning Objectives

- Understand the mammographic definitions of “mass,” “asymmetry,” “focal asymmetry,” and “global asymmetry” as described in BI-RADS, fourth edition.
- Discuss a practical work-up of asymmetric mammographic findings.
- Recognize the advantages, limitations, and pitfalls of supplementary mammographic views and other modalities for asymmetric mammographic findings.

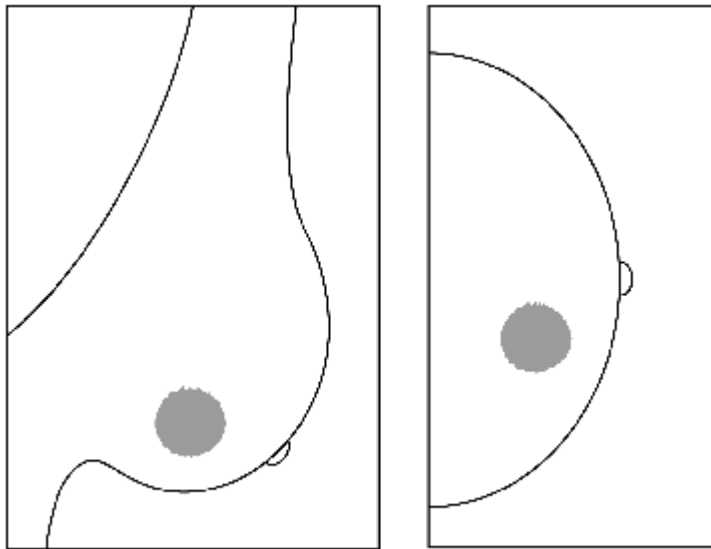
## Introduction

Although there is clearly wide variation in breast size and parenchymal pattern, the breasts have fairly symmetric internal structures with similar densities and architectures at mammography. However, asymmetric breast findings are relatively frequently seen at screening mammography (1). There is far from perfect symmetry between the breasts, and they are rarely symmetrically positioned during mammography. Findings of asymmetry at mammography are usually nonspecific and common in healthy women, but these findings are occasionally a secondary sign of malignancy (2). Therefore, each mammogram should be assessed for the presence of asymmetric findings. Once discovered, each finding should be analyzed appropriately to determine whether it represents a normal variant or something more significant. The American College of Radiology Breast Imaging Reporting and Data System (BI-RADS) has developed a lexicon for asymmetric findings. In 2003, with the publication of the fourth edition of BI-RADS (3), some changes were incorporated in that lexicon. In practice, however, many radiologists interpreting mammograms are not familiar with the lexicon or tend to apply inappropriate terminology to describe the asymmetric findings. We will review and clarify the terminology and changes regarding asymmetric breast findings in the fourth edition of BI-RADS and will discuss a practical work-up for characterizing and managing these findings, along with appropriate application of additional imaging studies. We will also illustrate cases of various conditions that cause asymmetric findings at mammography.

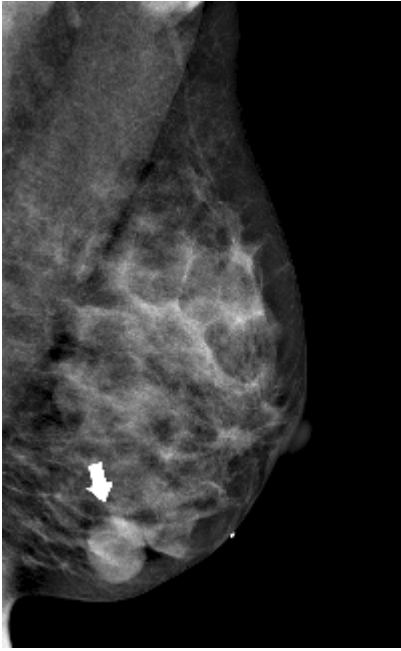## BI-RADS Lexicon Describing Asymmetric Findings: Third versus Fourth Edition

An asymmetric finding represents an area of tissue with fibroglandular density that is more extensive in one breast when judged relative to the corresponding region in the

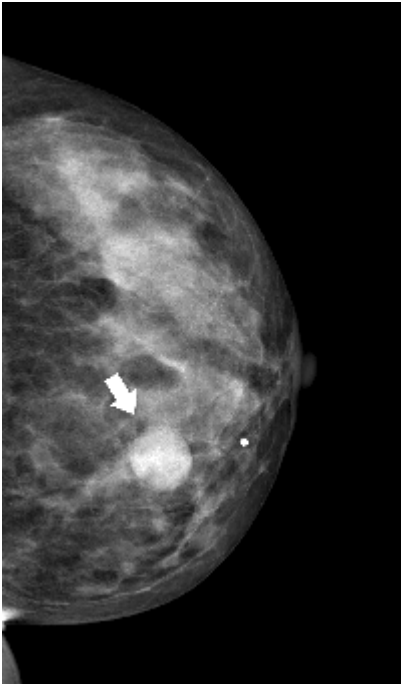
contralateral breast. In contrast to a mass, which is a three-dimensional structure demonstrating convex outward borders and which is usually evident on two orthogonal views, according to BI-RADS (Fig 1), asymmetric findings lack the convex outward borders and the conspicuity typical of a mass (3,4). In the third edition of BI-RADS (5), three types of asymmetric findings were described: density seen in only a single projection, asymmetric breast tissue, and focal asymmetric density. In the fourth edition (3), the term “density,” which describes a finding other than a mass, has been removed from the discussion of asymmetric findings owing to confusion with use of the term to describe x-ray attenuation characteristics of masses. Therefore, the new edition has replaced “asymmetric breast tissue” with “global asymmetry,” “density seen in only a single projection” with “asymmetry,” and “focal asymmetric density” with “focal asymmetry” (Table). The term “developing asymmetry” is not from the fourth edition of BI-RADS, in which there is only a brief description of “developing density,” but was introduced by Leung and Sickles (6). Because of its significance, developing asymmetry has been suggested as a separate category of asymmetry, one viewed with suspicion and warranting careful evaluation (3,6).



1a.



1b.



1c.

**Figure 1:** Mass seen in (a) schematic, (b) MLO view, and (c) CC views. The mass is seen as a space-occupying structure with convex outward borders (arrows).

## BI-RADS Lexicon Describing Asymmetric Findings

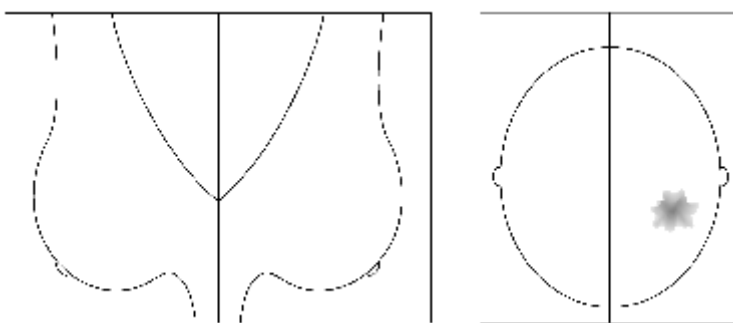
BI-RADS Edition	Finding			
	Fourth	Mass	Asymmetry	Focal asymmetry
Third	Mass	Density seen in only a single projection	Focal asymmetric density	Asymmetric breast tissue
No. of views showing finding	2	1	2	2
Definite convex outward border	Yes	No	No	No
Size of area involved	N/A	N/A	Less than a quadrant	At least a quadrant

Note.—N/A = not applicable.

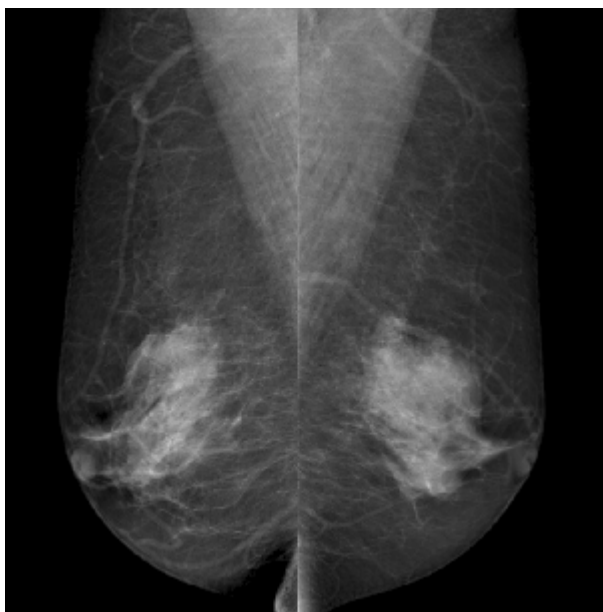
**Asymmetry (“Density Seen in Only a Single Projection” in Third Edition of BI-RADS)**

If a potential mass is seen in only a single view at standard mammography, it should be called an “asymmetry” until its three-dimensionality is confirmed. Asymmetries are planar and lack convex outward borders and the conspicuity of a three-dimensional mass (Fig 2). They usually contain interspersed fat. Summation shadow, which accounts for approximately 80% of cases of asymmetry, is caused by the superimposition of normal fibroglandular breast structures in a given mammographic projection (4). True lesions may appear on only one view because on other views they are either obscured by overlapping dense parenchyma or are located outside the field of view (1).

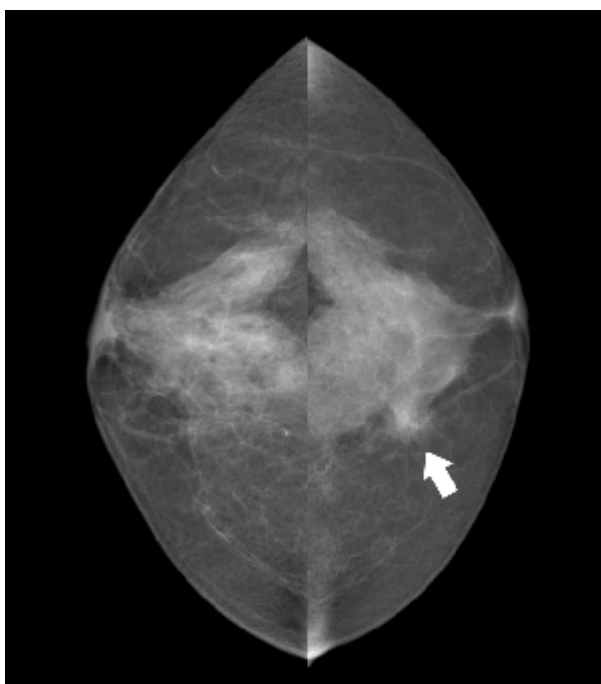
Teaching Point



2a.



2b.

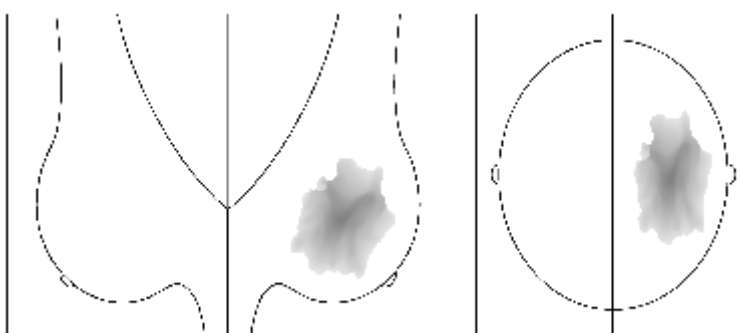


2c.

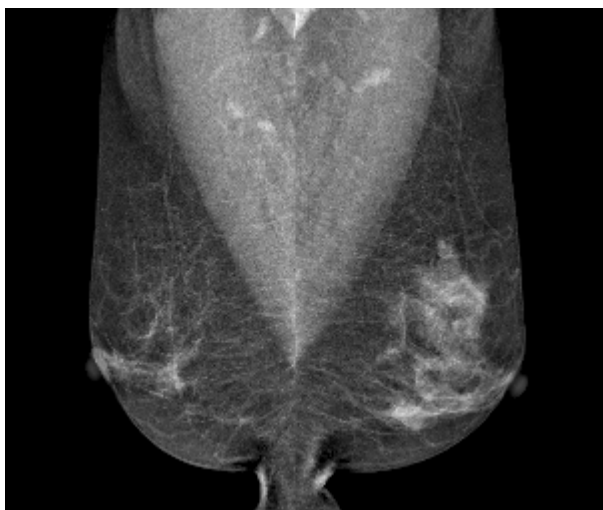**Figure 2:** Asymmetry seen in (a) schematic, (b) MLO views, and (c) CC views. A potential lesion lacking the characteristics of a mass is seen only on the left CC view (arrow). A corresponding abnormality is not seen on the left MLO view.

**Global Asymmetry (“Asymmetric Breast Tissue” in Third Edition of BI-RADS)**

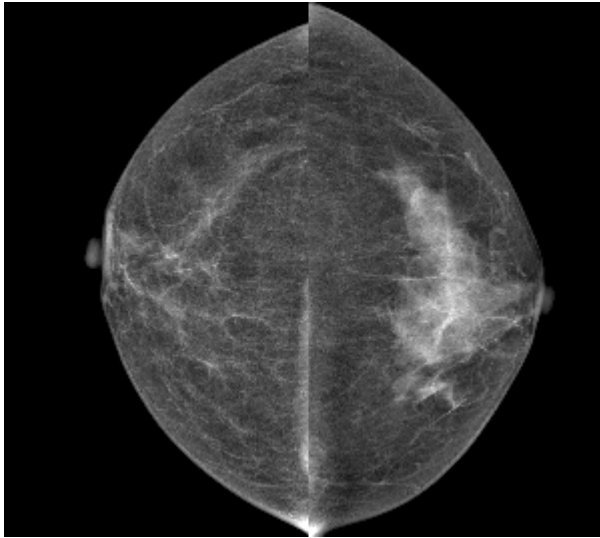
This asymmetric finding involves a greater volume of breast tissue over a significant portion of the breast (at least a quadrant), relative to the corresponding region in the contralateral breast, without any associated mass, suspicious calcifications, or architectural distortions (Fig 3). Global asymmetry has been reported in approximately 3% of mammographic examinations (4). It is usually due to normal variations or hormonal influence but may be significant when it corresponds to a palpable abnormality.

Teaching  
Point

3a.



3b.



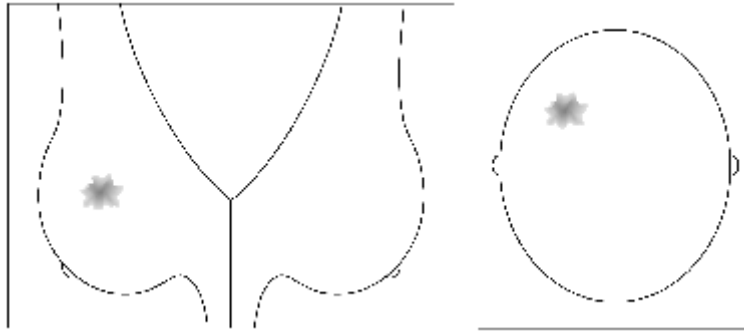
3c.

**Figure 3:** Global asymmetry seen in (a) schematic, (b) MLO views, and (c) CC views. A much greater volume of breast tissue is seen over a substantial portion of the left breast relative to the corresponding region in the right breast, but there is no associated mass, suspicious calcifications, or architectural distortion.

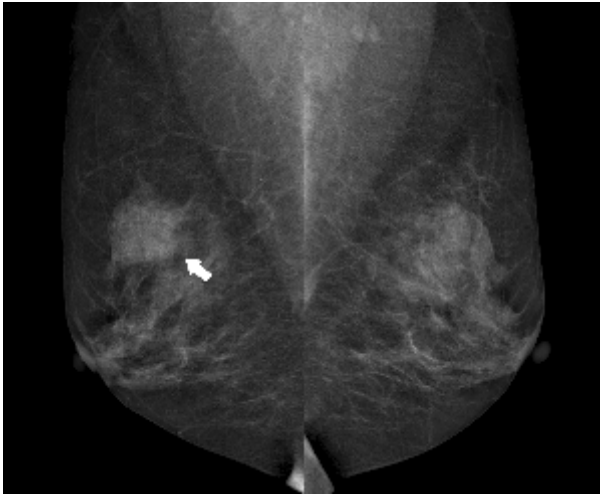***Focal Asymmetry (“Focal Asymmetric Density” in Third Edition of BI-RADS)***

Focal asymmetry is visible as a confined asymmetry with a similar shape on two views but does not fit the criteria of a mass: that is, it lacks convex outer borders and conspicuity (Fig 4). In contrast to global asymmetry, it occupies a volume of less than one quadrant of the breast and is of more concern. The frequency of finding focal asymmetry at screening mammography is less than 1% (4). A focal asymmetry could represent an island of normal breast tissue, particularly when there is interspersed fat, but its lack of specific benign characteristics warrants further evaluation because an ill-defined mass could appear to be a focal asymmetry at screening mammography.

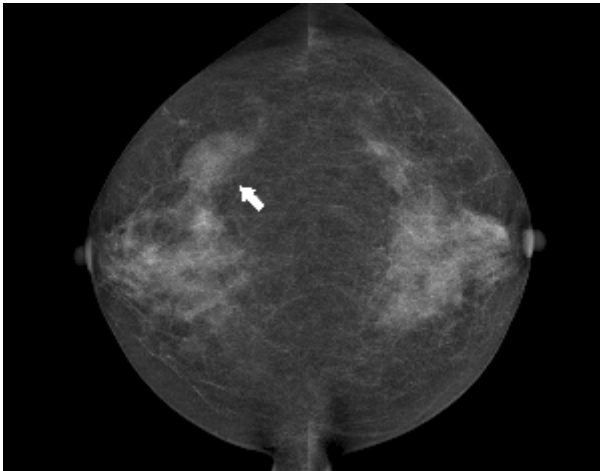
Teaching  
Point



4a.



4b.



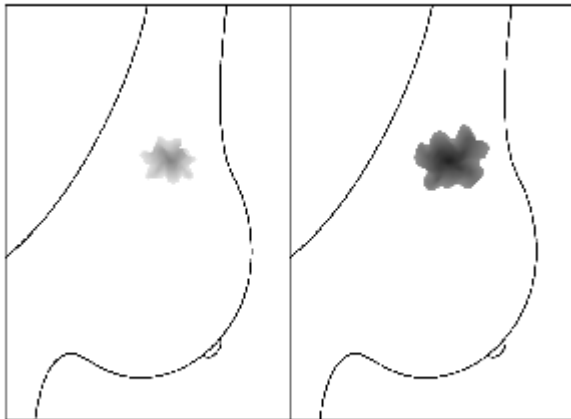
4c.

**Figure 4:** Focal asymmetry seen in (a) schematic, (b) MLO views, and (c) CC views.

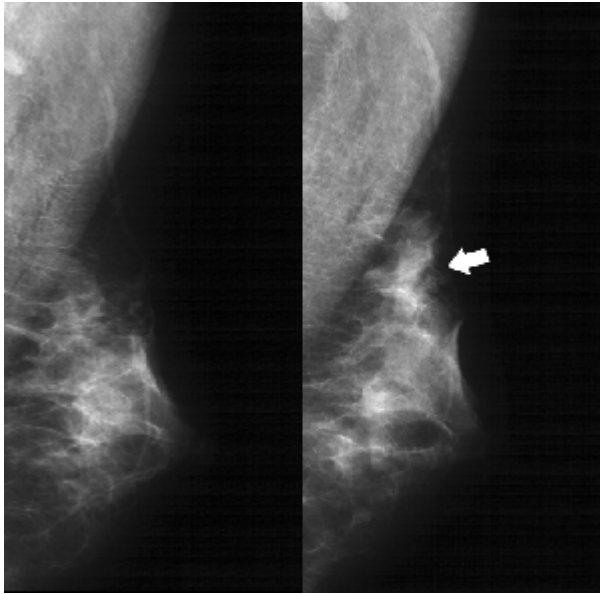
A focal asymmetry with a similar shape (arrows), not fitting the criteria of a mass, is seen on two standard views.

### *Developing Asymmetry*

This is a focal asymmetry that is new, larger, or denser at current examination than at previous examinations (Fig 5). To identify such a lesion, comparison with previous mammograms is critical. It raises a reasonable degree of suspicion and requires additional evaluation in the absence of a history of hormonal therapy, surgery, trauma, or infection at the site. It is an uncommon mammographic finding, reported in less than 1% of examinations, but the likelihood of malignancy ranges from 13% to 27% (Fig 6) (4).

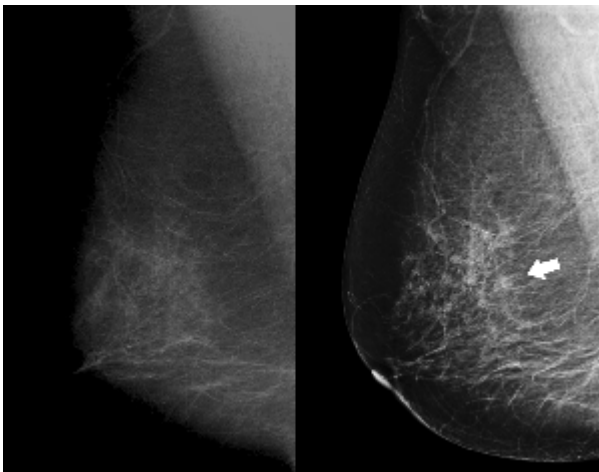


**5a.**

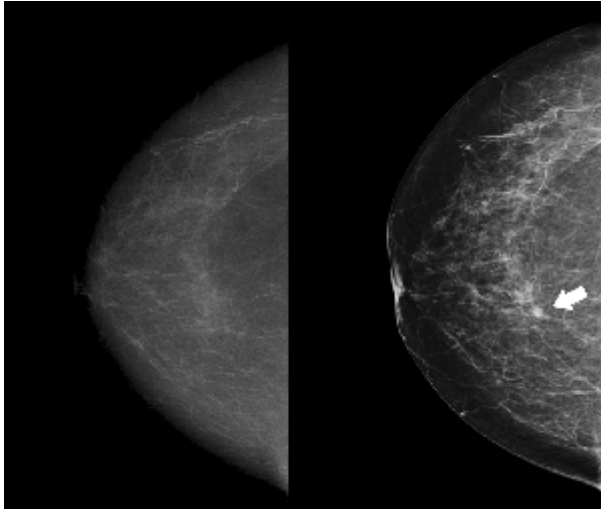


5b.

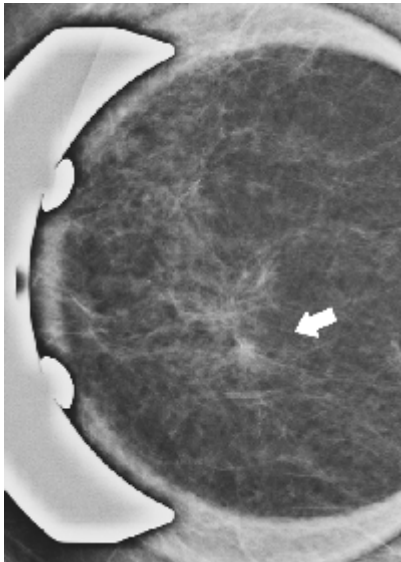
**Figure 5:** Developing asymmetry. (a) Schematic shows a developing asymmetry that is larger and denser on current examination (right) than on previous one. (b) A developing asymmetry is seen as a new focal asymmetry (arrow) on follow-up MLO view obtained 2 years after baseline mammogram (left).



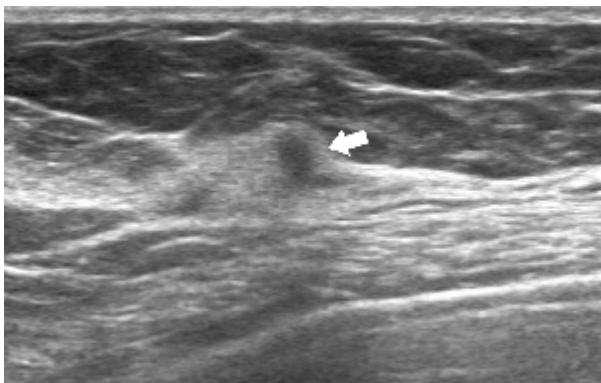
6a.



6b.



6c.



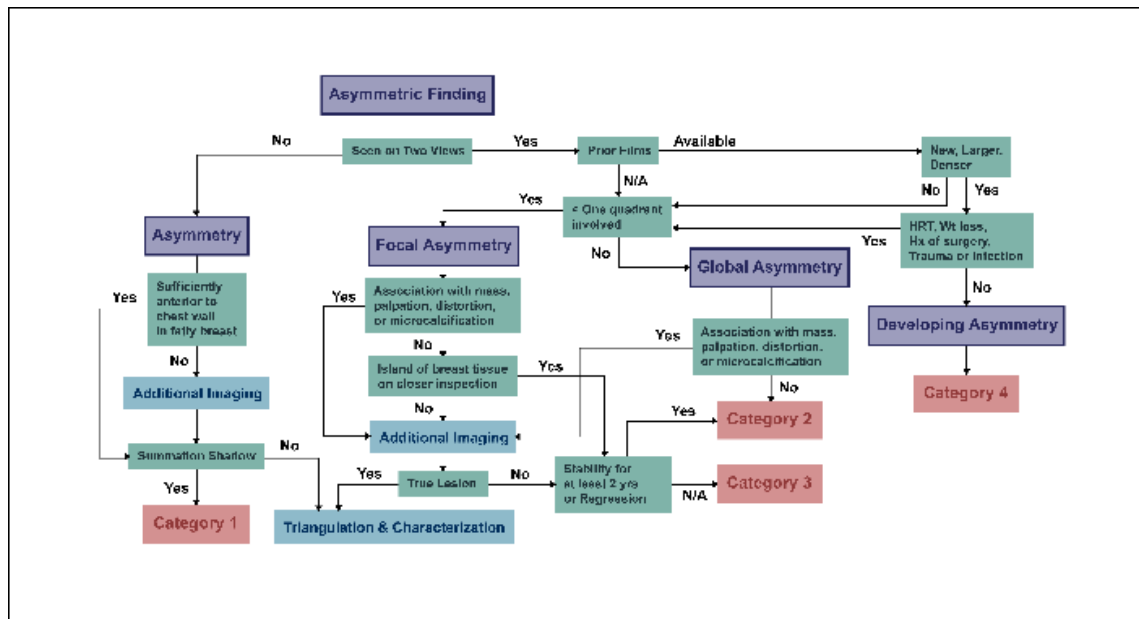
6d.

**Figure 6:** Malignancy seen as developing asymmetry in (a) MLO views and (b) CC views. Follow-up mammogram (right) obtained 1 year after baseline mammogram (left) shows a developing asymmetry in upper center of right breast (arrows). (c) Spot compression magnification view of the developing asymmetry shows a spiculated mass (arrow). (d) US scan shows a corresponding ill-defined nonparallel mass (arrow). After a core needle biopsy and subsequent mastectomy, invasive ductal carcinoma was confirmed.

### Imaging Evaluation and Management of Asymmetric Findings

Absolute symmetry of the breast is rarely observed. This is due in part to variations in breast development and differences in breast positioning and compression during the mammographic examination. Given the likelihood that breast positioning will vary from one examination to the next, it should be expected that regions of asymmetry will be seen at least in one view, and this may not correlate with a geometric focus on another view (7). However, not all cancers form a mass visible at mammography, and there is the potential of dismissing asymmetries simply because a mass is not evident. **Once such a potential abnormality is found, it is necessary to determine whether it is three-dimensionally real or just a projection artifact of superimposed normal structures. The tendency to rely on conventional projections only may be an obstacle to the proper evaluation of asymmetry. Although it can be inconvenient, it is better to have the patient return for additional evaluation than to make a management decision based on insufficient information.** A practical work-up algorithm that can be used for characterization and management of asymmetric breast findings is suggested in Figure 7.

Teaching  
Point

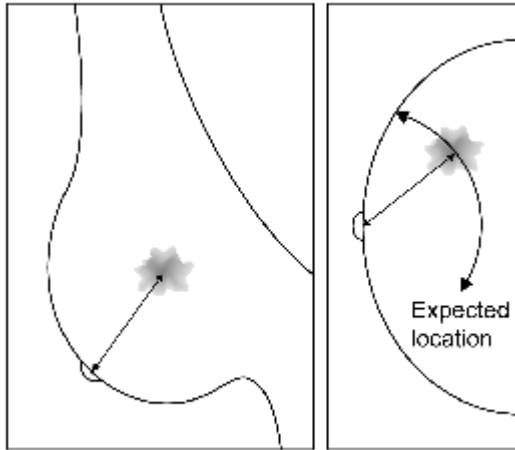


7.

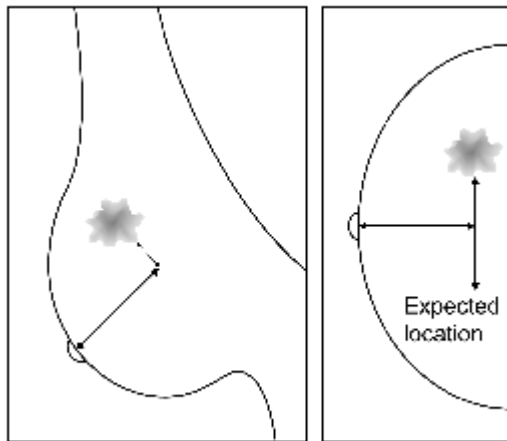
**Figure 7:** Work-up algorithm for the asymmetric breast findings. *HRT* = hormonal replacement therapy, *Hx* = history, *N/A* = not available, *Wt* = weight.

### Asymmetry

Comparing projections at mammography can be one of the methods for determining whether a suspected lesion is real, which means determining its location on the projection in which it appears and then evaluating the corresponding tissues on the other projection (8). It can be useful for differentiating asymmetry (seen on only a single view) from focal asymmetry (seen on two views). There are two methods for triangulating a lesion in two projections: the arc method and the straight-line method. The arc method uses the distance from the nipple to the lesion as the radius of an arc with the nipple as its center (Fig 8a). The straight-line method measures the distance straight back from the nipple to a point where it is perpendicular to a line from the lesion that is parallel to the chest wall (Fig 8b). The lesion should fall on an arc or line at the same distance from the nipple on both projections. If a corresponding asymmetric finding cannot be seen on the other projection, it is regarded as an “asymmetry.”



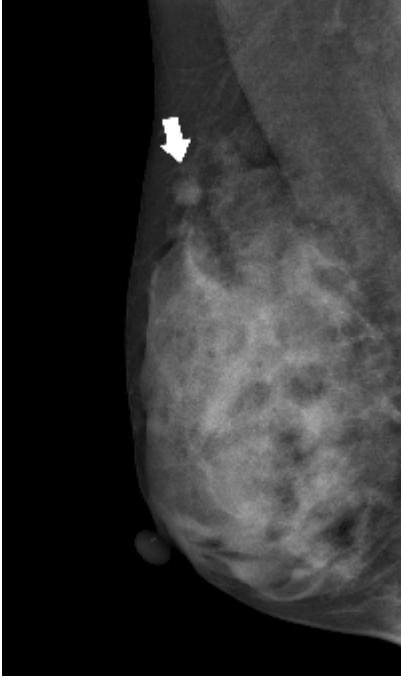
8a.



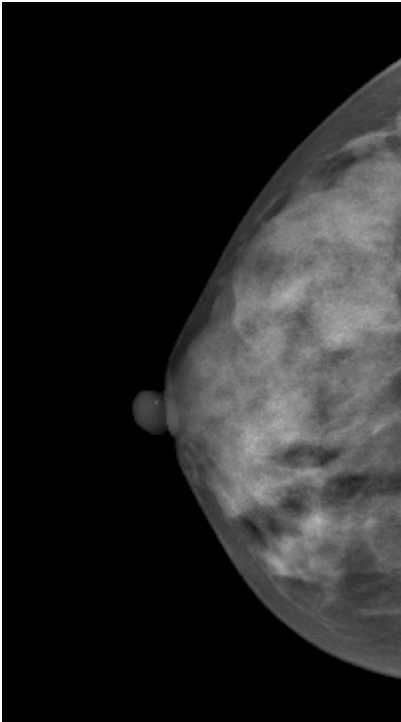
8b.

**Figure 8:** Schematics show two methods of looking for a corresponding finding on the other view. **(a)** Arc method. The distance from the nipple to the lesion is measured on one view and transferred to the other projection, and an arc is swept with the nipple as the center. The tissues along this arc must contain the suspected lesion on the second view. **(b)** Straight-line method. The distance straight back from the nipple to a point where it is perpendicular to a line from the lesion parallel to the chest wall is measured. This distance is transferred to the other projection. If the lesion is real, it should be somewhere along a line perpendicular to the transferred line at the same distance from the nipple.

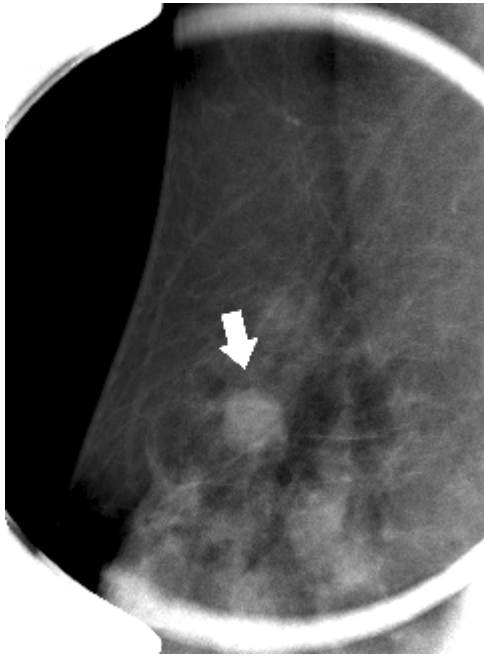
Although many asymmetries result from summation shadows (the superimposition of normal fibroglandular breast structures), true lesions may also appear on only one view when they are in anatomic locations beyond the limits of the image receptor (eg, in the axillary tail or in a posterior location [Fig 9]) or breast positioning during mammographic examination is not optimized to fully include all breast tissue (the difference in the posterior nipple line between two standard views is more than 1 cm [7,9]). Therefore, it should first be determined whether the asymmetric finding is likely to have been included in the other projection. If not, the situation is usually remedied by repeated or additional views tailored to ensure that the proper amount of breast tissue is on the image receptor to assess the finding in question. If yes, tailored additional mammographic views should be obtained to differentiate a true lesion obscured by overlapping dense parenchyma on the other projection from summation shadow. An asymmetry can confidently be assessed as representing summation shadow without the need for additional mammographic views when (a) the asymmetry is visible on only one of the two standard mammographic views, (b) the asymmetry is sufficiently anterior to the chest wall that it must be included in the image field on the other standard view, and (c) the breast has sufficient fat content that, on the standard view not showing the asymmetry, there is no concern about substantial additional dense tissue obscuring the asymmetry (4). Comparison with previous mammograms can be particularly helpful for detecting subtle new findings or reducing the recall rate or the false-positive rate, but stability cannot preclude work-up of suspicious findings.



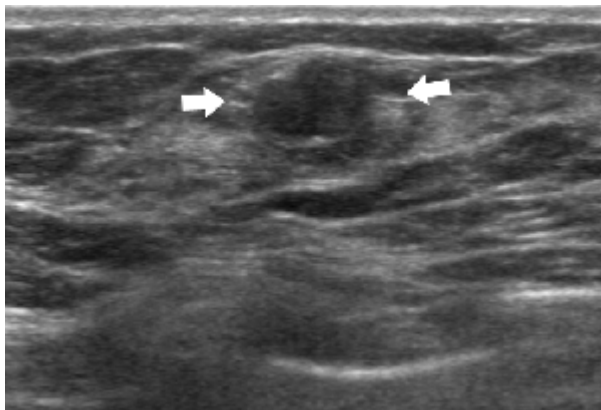
9a.



9b.



9c.

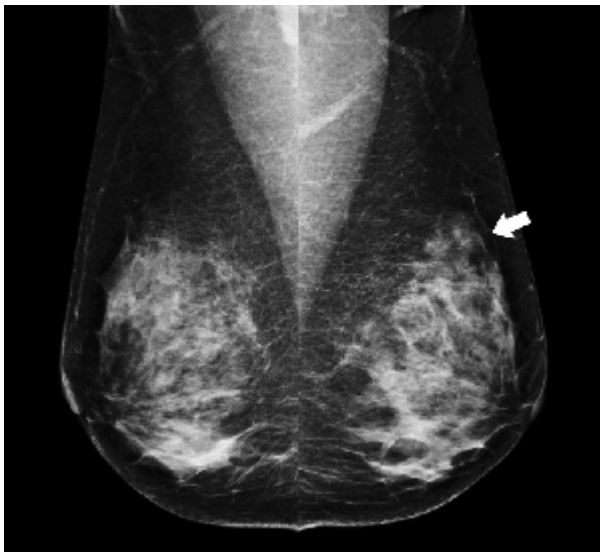


9d.

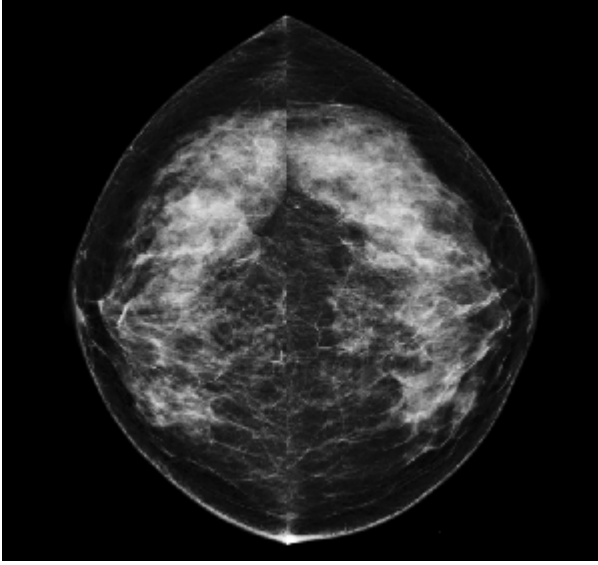
**Figure 9:** Asymmetry caused by anatomic location. A potential round mass lesion with a circumscribed margin (arrow) is seen (a) on the right MLO view but is not seen on the (b) right CC view. (c) Spot compression magnification view depicts the lesion (arrow) more clearly. (d) US scan shows the corresponding mass (arrows) in the right axillary tail. It was diagnosed as a fibroadenoma.

For further evaluation of asymmetry seen on one projection, it is best to return to that projection and alter it slightly to determine whether the finding is real (8). The real lesion is unlikely to change its appearance, regardless of the angle of projection. A

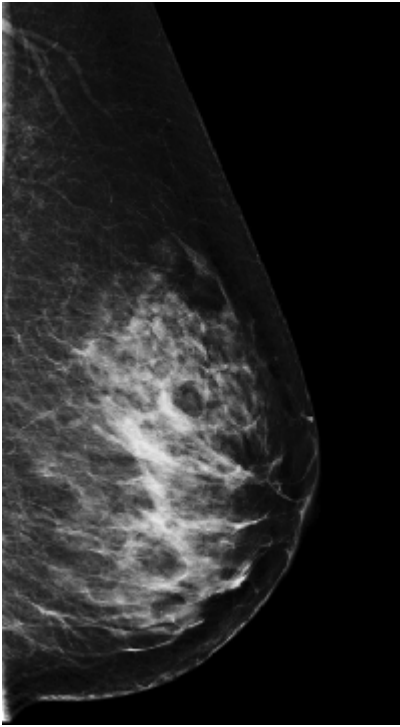
straight lateral view for an asymmetry seen only on a mediolateral oblique (MLO) view and a rolled view for an asymmetry seen only on a craniocaudal (CC) view should be obtained. If the asymmetry is maintained even after the angle of projection is changed, additional views in other projections should be obtained. For example, an asymmetry initially seen on a CC view may appear on the straight lateral view when not initially seen on the MLO view. If the asymmetry is not seen on additional views, which is sufficient for a confident diagnosis of summation shadow, the radiologist can render a BI-RADS category 1 assessment and recommend routine mammographic screening after 1 year (Fig 10) (4). For findings proved to be real, the next step should be to triangulate the three-dimensional location precisely on orthogonal mammographic views. This permits accurate placement of the spot-compression paddle for additional standard or magnification views, or targeted ultrasonography (US) to characterize the lesion more clearly and specifically (4).



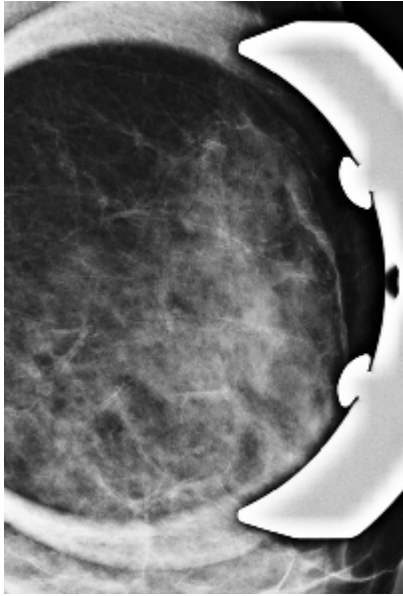
10a.



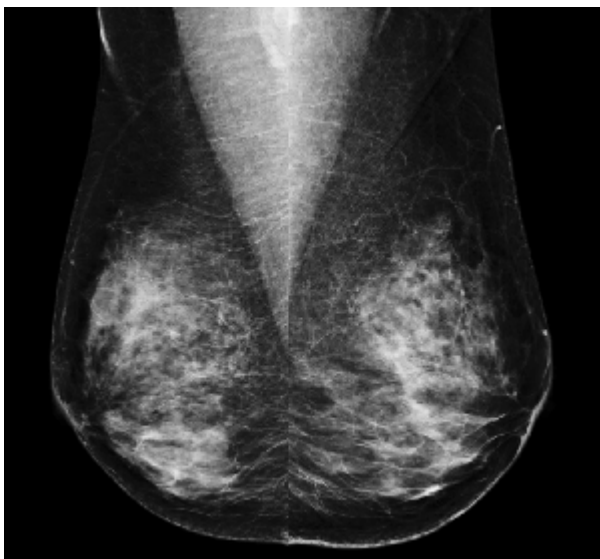
10b.



10c.



10d.

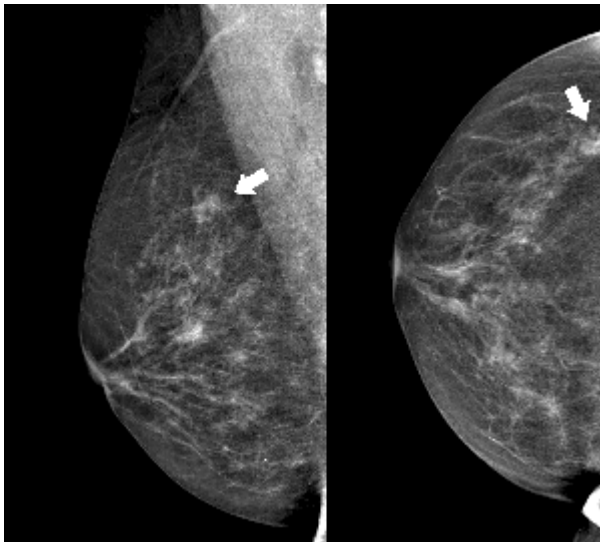


10e.

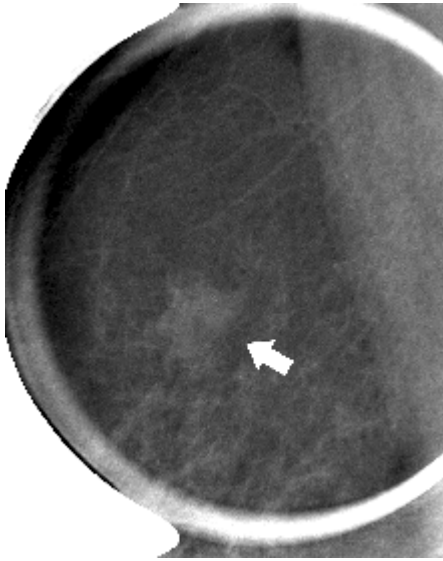**Figure 10:** Asymmetry representing summation shadow. **(a)** MLO and **(b)** CC views: Asymmetry is seen only on the left MLO view (arrow). **(c)** On the straight lateral view and **(d)** spot compression magnification view, obtained for further evaluation, the asymmetry disappears. **(e)** Follow-up mammography after 2 years shows no interval change.

### *Focal Asymmetry*

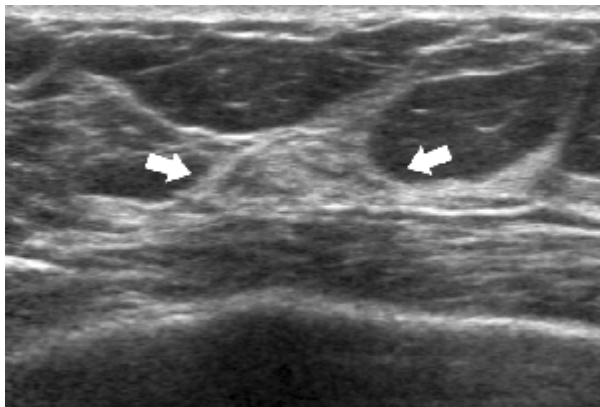
If an asymmetric finding is three-dimensionally real (ie, seen on two projections), the observer must decide whether this is caused by an island of normal breast tissue or a true lesion. The vast majority of focal asymmetries represent an island of breast tissue that is usually apparent on closer inspection with dissection of the components of the asymmetric volume, showing that they are unrelated superimposed structures (10). Fat can be seen dispersed within the tissue (Figs 11, 12). The island of breast tissue does not form a mass and demonstrates no associated architectural distortion, spiculation, or significant calcifications. A lack of specific benign characteristics may warrant further evaluation. A focal asymmetry should be considered suspicious if its density is concentrated at its center. The finding becomes more suspicious when it is not diffuse but rather focused around a point in the breast (11). If the finding corresponds to a palpable abnormality, it is also considered suspicious. In these cases, additional evaluations are required to determine whether the focal asymmetry is actually a mass. Spot compression views, rolled views, or different angles of the x-ray beam may help spread or reorient tissue structures to help define and characterize an underlying lesion more clearly (Figs 13, 14).



**11a.**

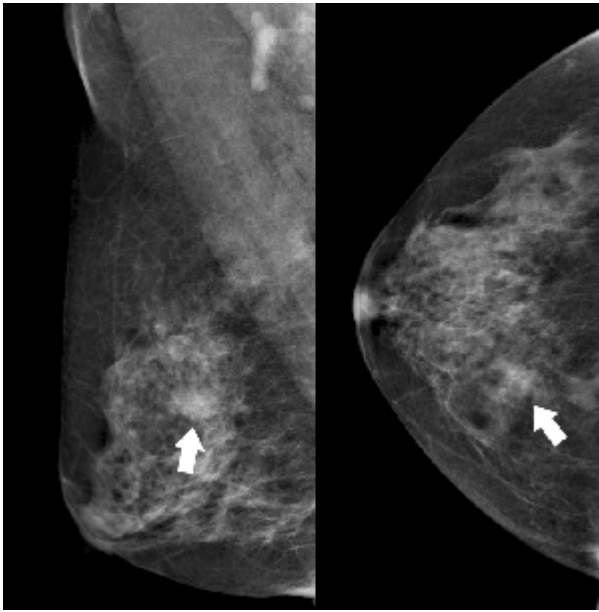


11b.

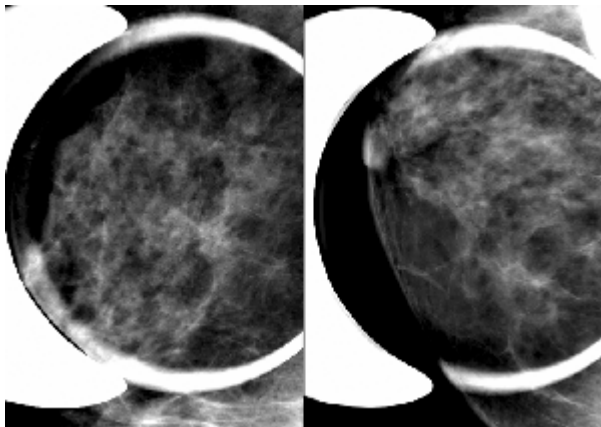


11c.

**Figure 11:** Focal asymmetry representing an island of breast tissue. **(a)** Mammographic views show a focal asymmetry in the right upper outer region (arrows). **(b)** Spot compression magnification view demonstrates that the focal asymmetry has decreased density interspersed with fatty density (arrow). **(c)** US scan demonstrates an island of normal breast tissue (arrows) that corresponds to the focal asymmetry seen at mammography.

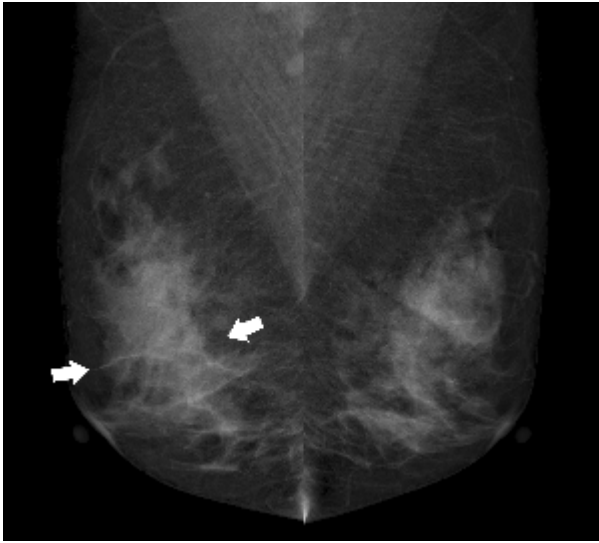


12a.

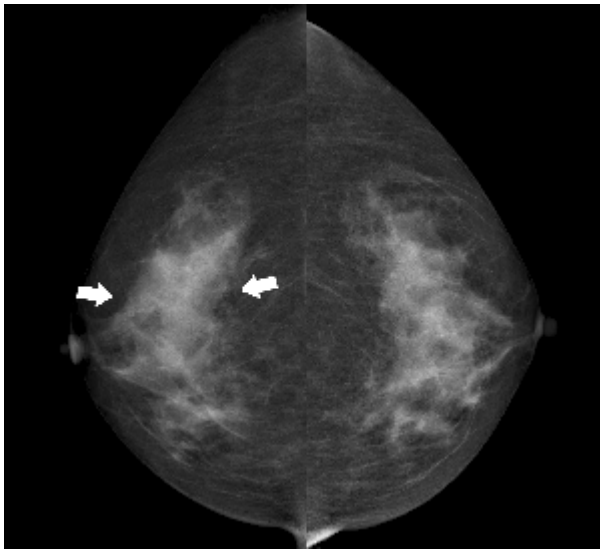


12b.

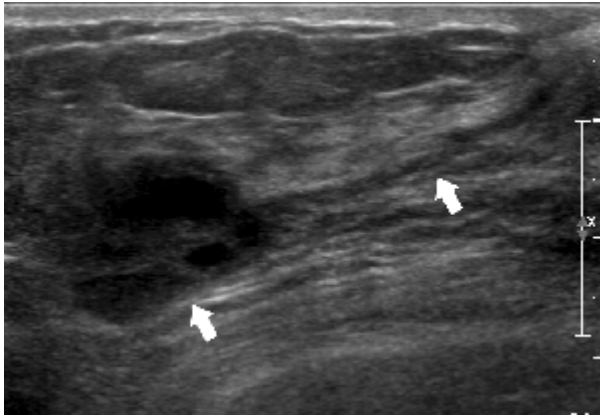
**Figure 12:** Focal asymmetry representing summation shadow. **(a)** Mammographic views show a focal asymmetry in the right upper medial area (arrows). **(b)** On the spot compression magnification views (left, 90° view; right, CC view), the focal asymmetry disappears.



13a.

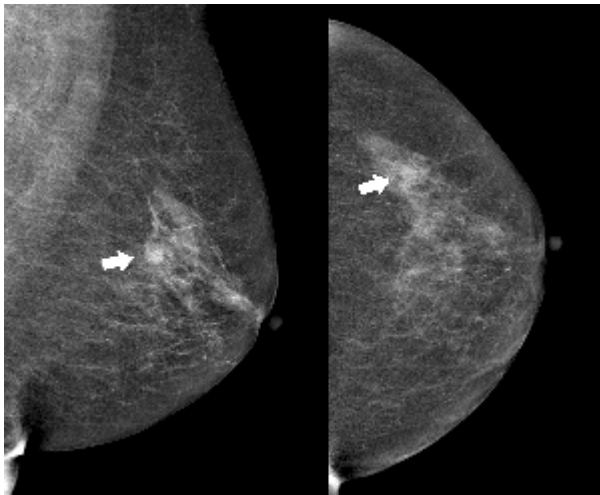


13b.

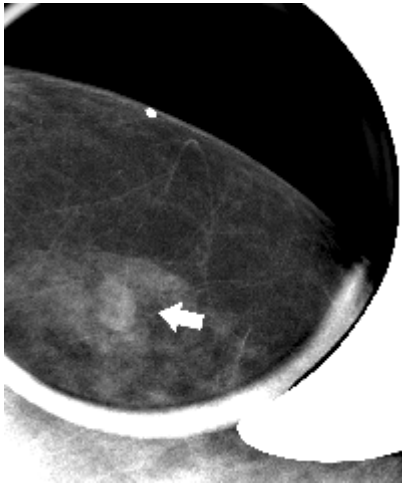


13c.

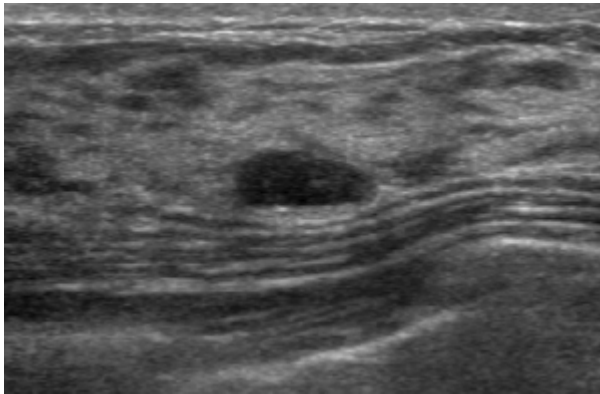
**Figure 13:** Focal asymmetry representing malignancy. (a) MLO views and (b) CC views show a focal asymmetry (arrows). (c) US scan shows a spiculated mass with a ductal abnormality (arrows) assessed as BI-RADS category 5. Pathologic diagnosis of the lesion proved an invasive ductal carcinoma.



14a.



14b.

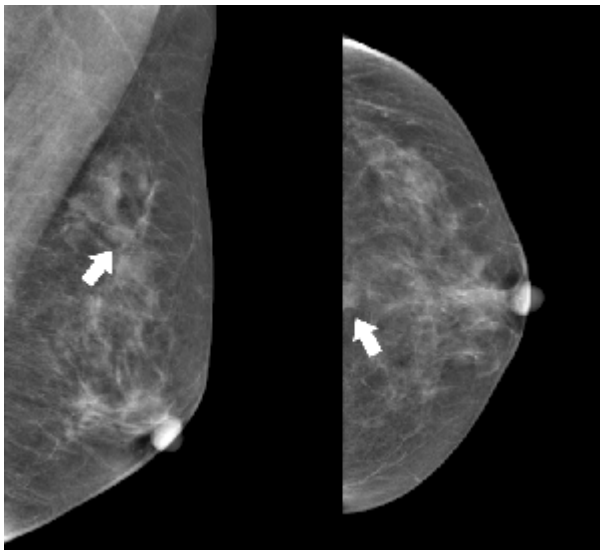


14c.

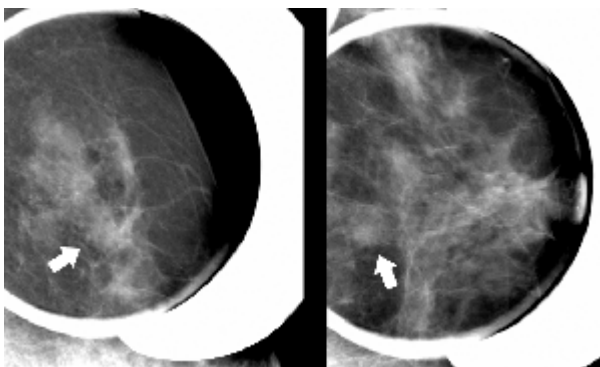
**Figure 14:** Focal asymmetry representing a probably benign finding. **(a)** Mammographic views show a focal asymmetry (arrows). **(b)** Spot compression magnification view and **(c)** US scan show an oval, circumscribed mass (arrow) assessed as BI-RADS category 3.

If no previous mammograms are available for comparison, nonpalpable focal asymmetries with no associated mammographic or sonographic abnormalities are often assessed as probably benign (BI-RADS category 3), with a recommendation for periodic mammographic surveillance: follow-up at 6 months, 1 year, and 2 years before returning to screening (Figs 7, 15) (4). When previous mammograms are available for comparison, demonstration of short-term (1 year) stability eliminates the need for 6-month follow-up but usually requires annual follow-up until 2-year stability is shown. Demonstration of lesion stability for at least 2 years or demonstration of lesion

regression justifies a definitive benign assessment (BI-RADS category 2) (Fig 16). Lesion progression effectively establishes the diagnosis of developing asymmetry, which is assessed as suspicious (BI-RADS category 4) and requires tissue diagnosis.] **TP** [Focal asymmetry associated with palpable findings, architectural distortion, microcalcifications, or an underlying solid mass should be properly managed according to the final assessment from diagnostic mammography or ancillary imaging modalities.]



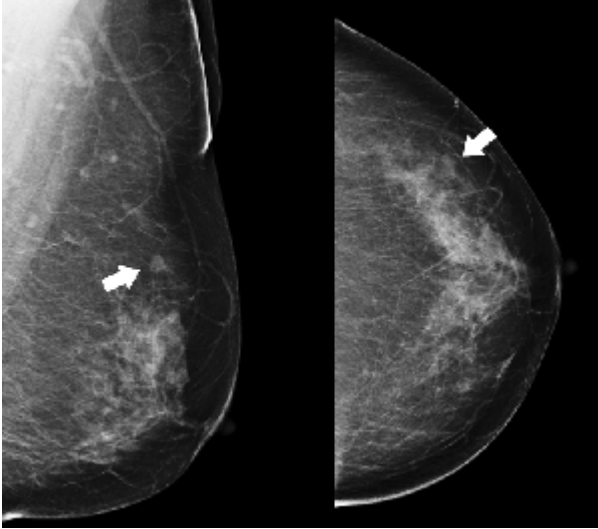
15a.



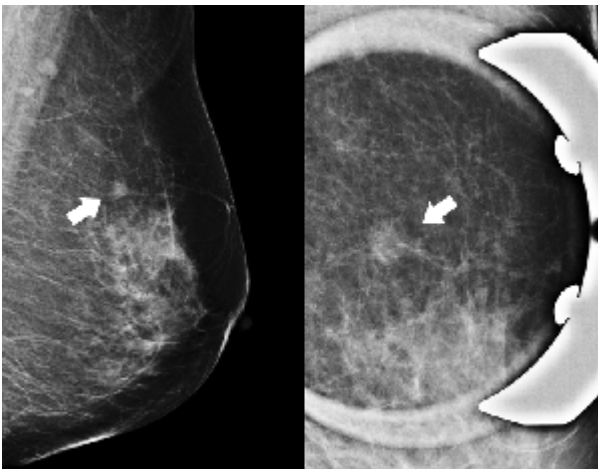
15b.

**Figure 15:** Focal asymmetry representing a probably benign finding. **(a)** Mammographic views show a focal asymmetry (arrows). **(b)** Spot compression magnification views (left, straight lateral view; right, CC view) show the focal asymmetry (arrows) is neither changed nor associated with other suspicious mammographic abnormalities. No previous mammograms were available for

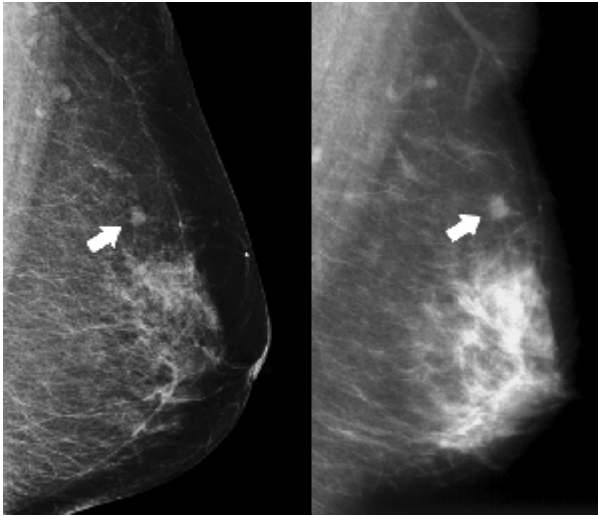
comparison, and there were no associated sonographic abnormalities (not shown). The finding was assessed as BI-RADS category 3.



16a.



16b.

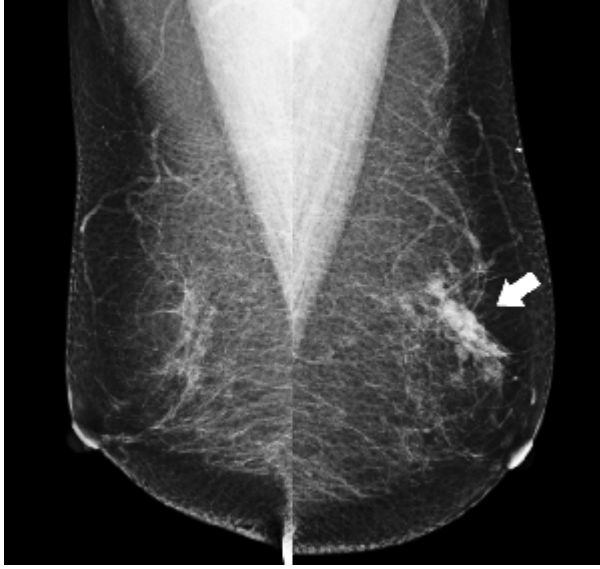

**16c.**

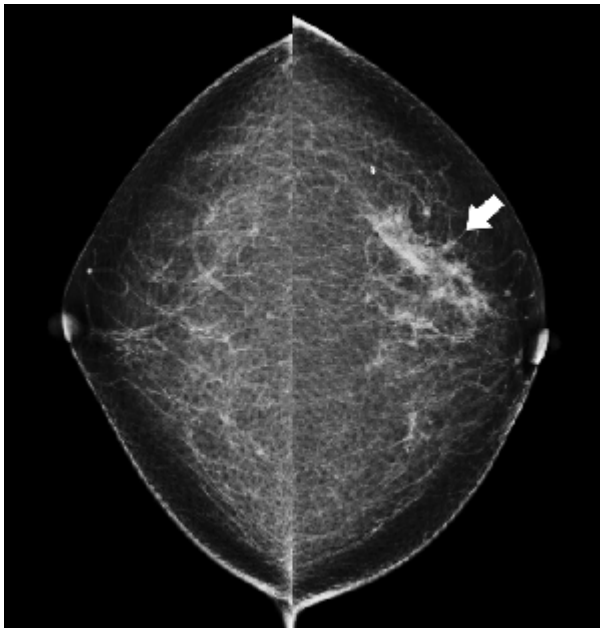
**Figure 16:** Focal asymmetry representing a benign finding. **(a)** Mammographic views show a focal asymmetry (arrows). **(b)** Additional mammographic views (left, straight lateral view; right, spot compression magnification view) still show the asymmetry (arrows). **(c)** Previous mammograms available for comparison (left, obtained 2 years previously; right, obtained 4 years previously) show that this finding was stable over 4 years. US (not shown) did not demonstrate any abnormal findings in the corresponding region. The finding was assessed as BI-RADS category 2.

### ***Global Asymmetry***

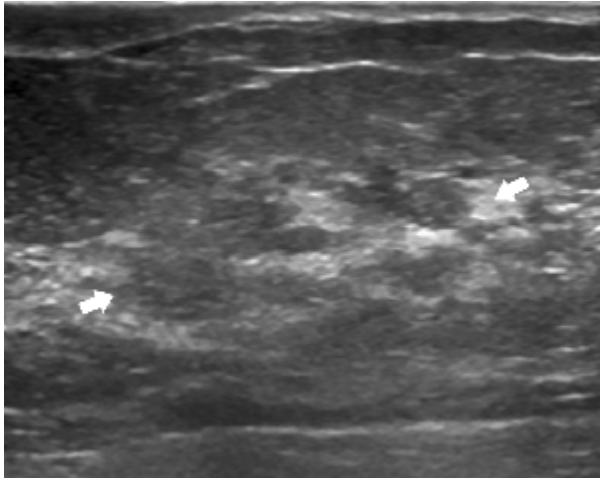
This finding is almost always benign and requires no additional evaluation if there are no corresponding palpable abnormalities, architectural distortions, significant calcifications, or masses (BI-RADS Category 2) (4). This finding is due either to a developmental variant or to differential end-organ response to hormonal stimuli (11). It should not develop in a previously normal tissue volume. However, differences in imaging techniques and positioning, weight loss, hormone replacement therapy, or surgical procedures could cause global asymmetry. Occasionally, it may indicate the presence of an underlying breast cancer if it corresponds to a palpable abnormality (Fig 17) (12). In this clinical setting, the radiologist should recall the patient for additional imaging evaluation (Fig 7).



17a.



17b.

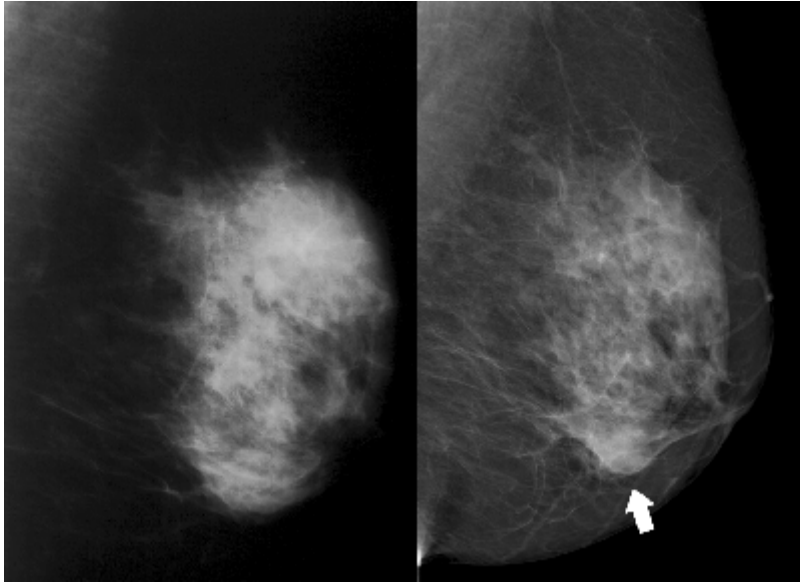


17c.

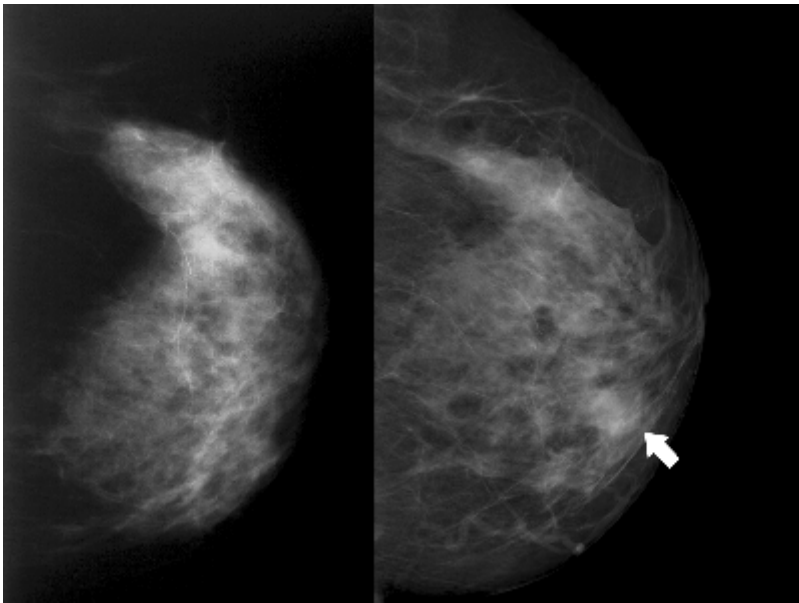
**Figure 17:** Global asymmetry representing malignancy. **(a)** MLO and **(b)** CC mammographic views show global asymmetry (arrows) in left upper outer region of breast corresponding to a palpable abnormality. **(c)** US scan demonstrates suspicious ductal abnormalities (arrows) in corresponding region of breast. This finding was diagnosed as ductal carcinoma in situ.

### *Developing Asymmetry*

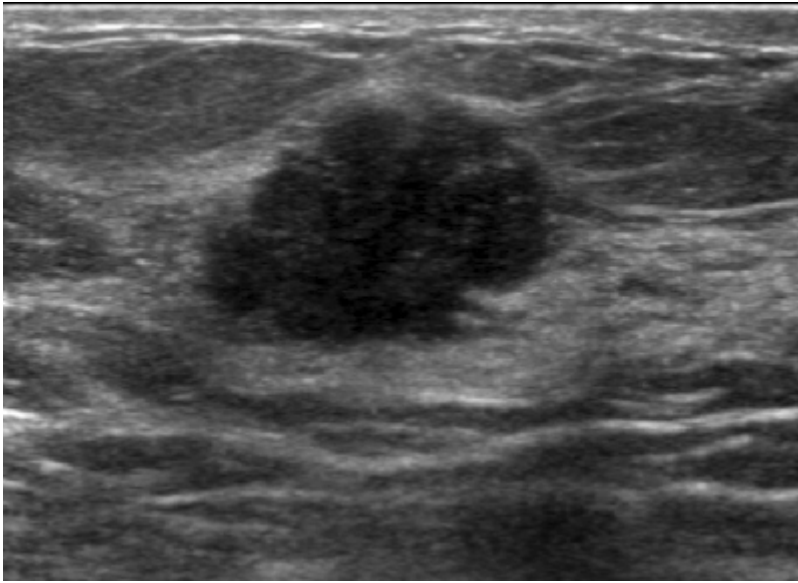
The finding of developing asymmetry at mammography, which is inherently suspicious (BI-RADS Category 4), should be evaluated with additional imaging or biopsy to identify possible cancer (Fig 18). To appreciate this phenomenon, it is important to compare the current study with previous studies performed at least 2 years earlier, if available, because an area of increasing density may not be apparent over a shorter follow-up period (2). A developing asymmetry that cannot be accounted for by differences in imaging technique and positioning or attributed to weight loss, hormone replacement therapy, surgery, trauma, or infection at the site should raise suspicion. If a focal asymmetry develops in a patient undergoing hormone replacement therapy, repeat mammography after discontinuation of therapy may demonstrate resolution of the finding. If the density does not resolve, biopsy is indicated. A developing asymmetry that becomes less evident but still persists after discontinuation of hormone replacement therapy could hypothetically represent estrogen-sensitive breast cancer (1).



18a.



18b.



**18c.**

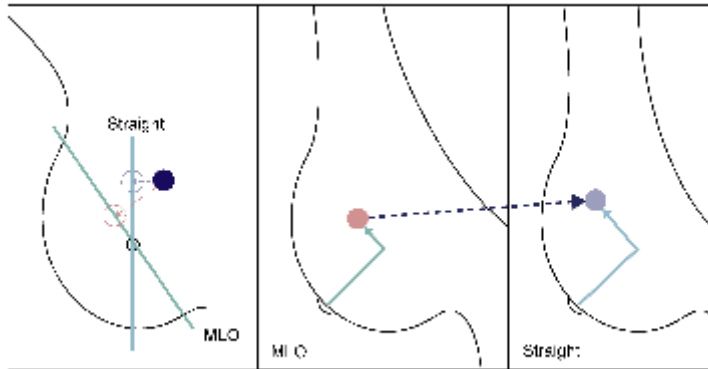
**Figure 18:** Developing asymmetry representing malignancy. **(a)** MLO and **(b)** CC mammographic views show that a new focal asymmetry (arrows) has developed in the left lower medial breast region over 3 years (left, previous mammograms; right, current mammograms). **(c)** US scan shows that the developing asymmetry corresponds to a suspicious microlobulated hypoechoic mass that was assessed as BI-RADS category 4C, which was confirmed as invasive ductal carcinoma.

### **Additional Imaging Studies for Asymmetric Findings**

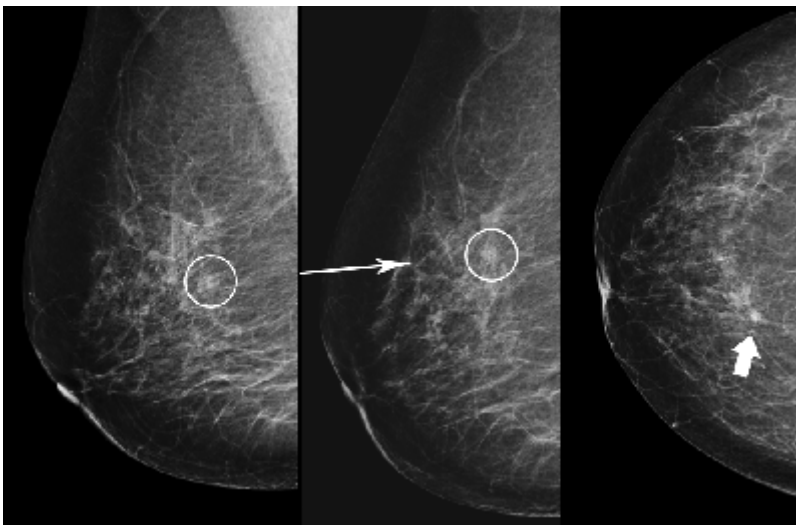
#### ***Straight Lateral View***

For an asymmetry seen only on the MLO view, it is frequently best to go immediately to the straight lateral view (8). This slight shift in the orientation of breast structures relative to the x-ray beam is often sufficient, by the disappearance or changed appearance of the asymmetry, to demonstrate that the abnormality is not real but rather a summation shadow. If the lesion is real, its shift relative to background breast tissues between the two projections can separate unrelated superimposed structures and help determine its location. This information can be used to guide positioning in the CC view to confirm the three-dimensional location of the lesion (ie, triangulation) (Fig 19). This maneuver is more successful the greater the angle change (eg, 45° MLO to 90° true lateral) between the two views. However, the anatomy of some women (orientation and strength of the pectoralis major muscle) does not permit a well-compressed 45° to 60°

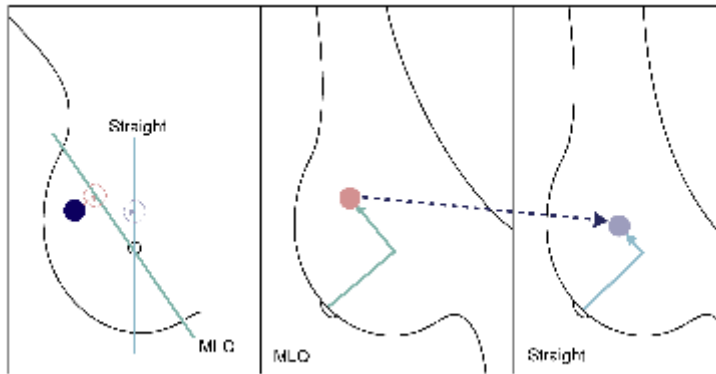
MLO projection to be obtained. In addition, sometimes breast tissue distribution (because of its weight and difficulty in positioning) will not appear to change appreciably from the MLO view to the lateral view (7).



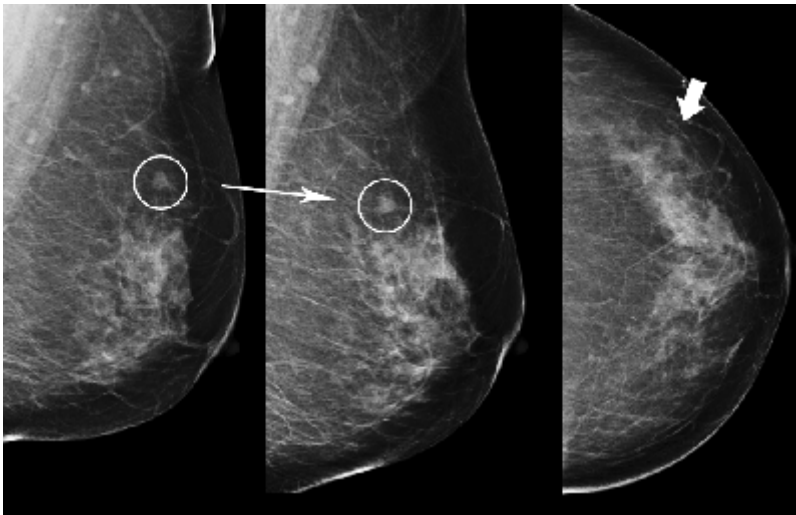
19a.



19b.



19c.



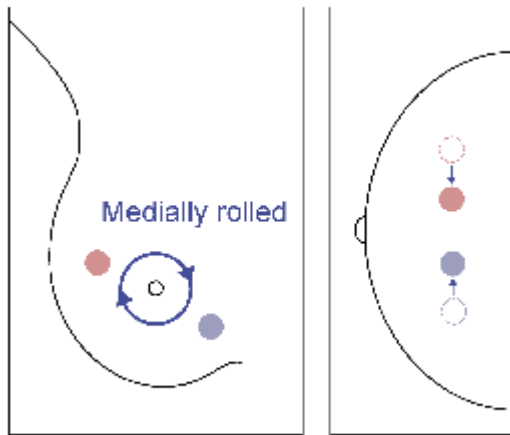
19d.

**Figure 19:** Use of straight lateral view for triangulation of asymmetry on MLO view. **(a)** Schematic shows that the lesion (solid circles) in the medial aspect of the breast moves up from the MLO view to the straight lateral view. The location of the blue dotted circle is the expected distance of the lesion from the nipple in the straight lateral view. The location of the pink dotted circle is the expected distance of the lesion from the nipple in the MLO view. According to these expected distances from the nipple (solid arrows), the location of the lesion on the MLO and straight lateral views is marked, and the broken arrow indicates that the lesion moves up from the MLO view to the straight lateral view. **(b)** The lesion (circle) on the MLO view (left panel) moves up on the straight lateral view (indicated by arrow in middle panel), which makes the lesion location (thick arrow) on the CC view (right panel) in the medial aspect of the breast.

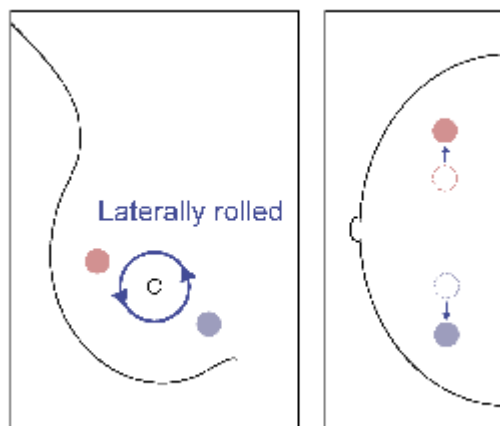
(c) Schematic shows that the lesion in the lateral aspect of the breast moves down from the MLO view to the straight lateral view. (d) The lesion (circle) on the MLO view (left panel) moves down on the straight lateral view (indicated by arrow in middle panel), which makes the lesion location (thick arrow) on the CC view (right panel) in the lateral aspect of the breast.

### ***Rolled View***

For asymmetries seen only on CC projections, the rolled view is best for determining the presence of a lesion (8). To obtain this view, the breast can be gently rotated around the axis of the nipple and recompressed in this new orientation. Rolling the breast will do little to obscure a true lesion, which will simply be displaced in the direction of the applied roll. Conversely, rolling the breast in an appropriate manner will cause a summation shadow to virtually disappear because the relevant tissues will be displaced with regard to one another. To properly determine the presence of a lesion, the direction of roll should be chosen so that the region in question is rolled toward and projected over an area of fat and not over dense tissue, so that the lesion is not obscured. This requires preliminary assessment of the fibroglandular pattern. If a true lesion is rolled into an area of dense fibroglandular tissue, it may be obscured, leading to the erroneous conclusion that it has "disappeared." Therefore, each rolled projection must be tailored for each patient (7). In addition, movement of a true abnormality relative to the background of the breast on the rolled view may indicate its location in the upper or lower breast and guide positioning in the lateral projection to confirm this location (Fig 20).



20a.



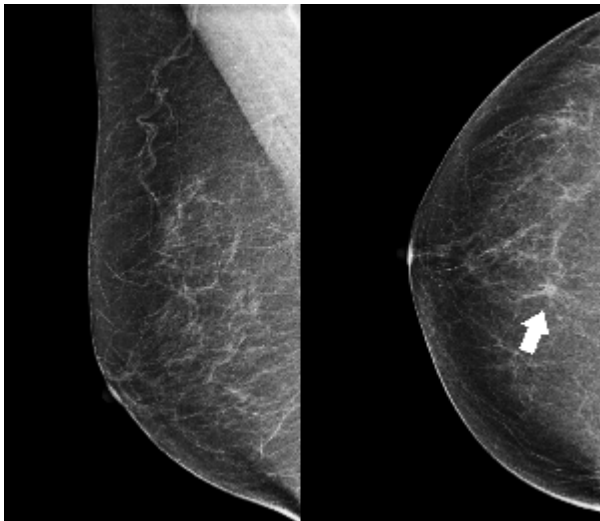
20b.

**Figure 20:** Use of rolled view in triangulation of asymmetry on CC view. **(a)** Schematic demonstrates that if the top of the breast is rolled medially while the lower part is rolled laterally, the lesion in the upper portion of the breast moves medially and the lesion in the lower portion moves laterally. **(b)** If the top of the breast is rolled laterally, the lesion in the upper portion of the breast moves laterally and the lesion in the lower portion moves medially.

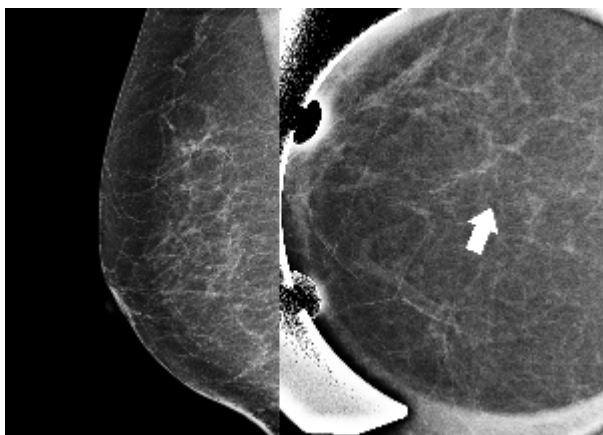
### *Spot Compression View*

A common method used for assessing an asymmetric breast finding is the spot

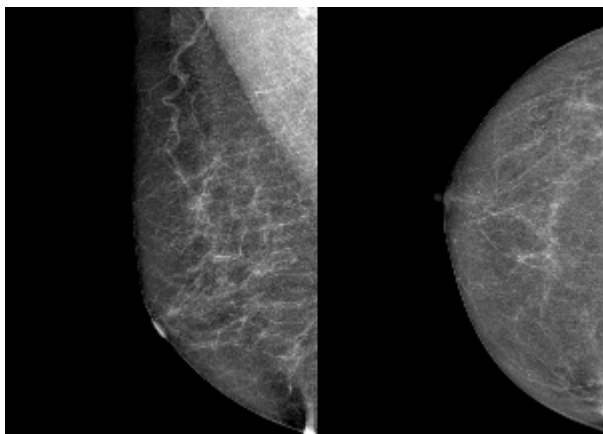
compression view with or without magnification, depending on the preference of the investigator. By subjecting a small focus to more targeted and vigorous compression, a summation shadow due to normal fibroglandular tissue that is more pliable is more likely to spread apart, revealing no focal abnormality (Fig 21). However, true lesions will preserve their characteristics when overlying or adjacent fibroglandular tissue is spread in different directions, allowing better characterization of the lesions (13). This presumption applies particularly to cancers, where the lesion and surrounding desmoplastic or fibrotic response are less likely to change their appearance, even with vigorously applied focal compression (Fig 22) (7). However, there are uncommon exceptions to this general observation. First, some cancers that are either not associated with a high density of tumor cells or with a sufficient desmoplastic response may be pressed out during spot compression views, leading to the erroneous conclusion that the area of concern represents summation shadow. Therefore, never just spot compress an asymmetry on one view; always obtain additional views in both projections, since even malignancies may spot compress away. Second, some regions of the breast in which there is a more focal accumulation of fibrotic tissue may be accordingly more resistant to being spread apart by spot compression. When asymmetries are fixed and focal but appear to spread out with spot compression, US may be valuable in averting the erroneous conclusion that a lesion does not exist (7).



21a.

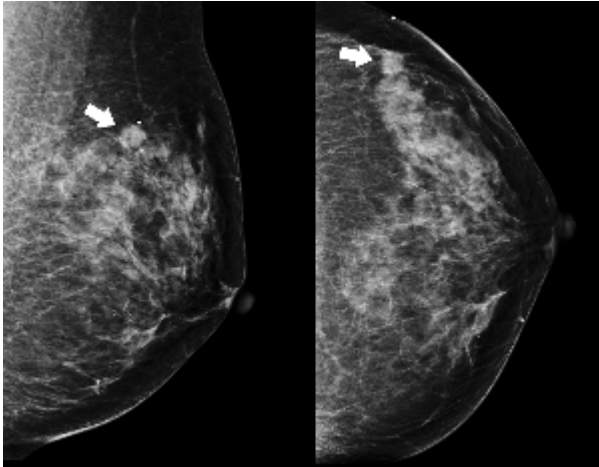


21b.

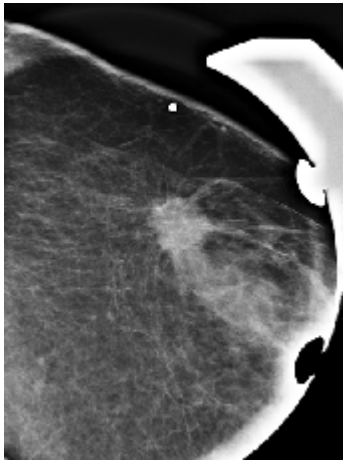


21c.

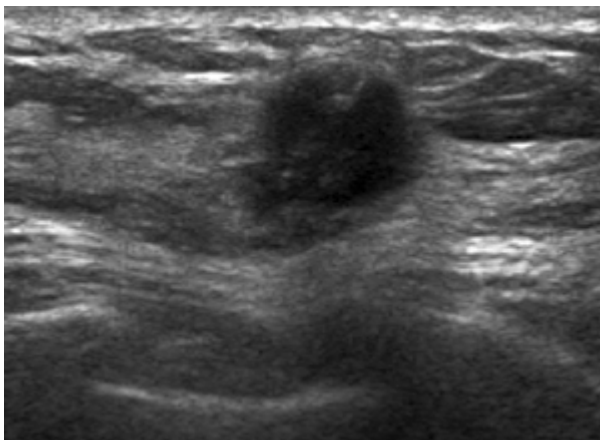
**Figure 21:** Use of spot compression view to demonstrate summation shadow. **(a)** Asymmetry (arrow) is seen on CC view of right breast. **(b)** For further evaluation of the asymmetry, a straight lateral view (left) and spot compression magnification view (right) were obtained. The asymmetry disappears (arrow), and no abnormality is seen on either image. **(c)** Mammograms of right breast obtained after 2 years do not show any abnormal findings.



22a.



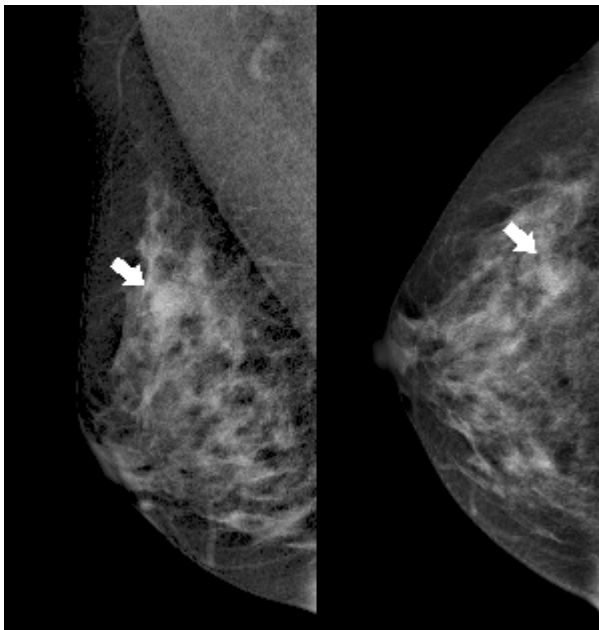
22b.



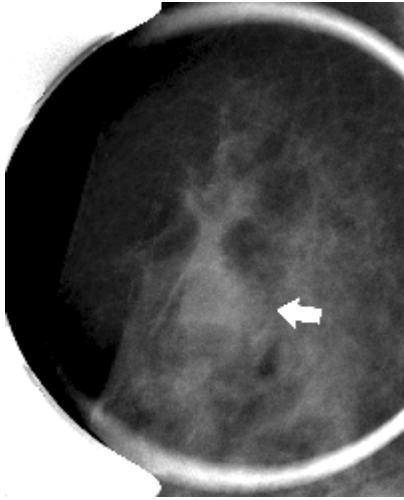
22c.

**Figure 22:** Use of spot compression view to demonstrate malignancy. **(a)** Mammographic views show a focal asymmetry (arrows). **(b)** After spot compression, the lesion proves real, its conspicuity and delineation are improved, and its characteristics—round shape and associated long spiculations—are revealed. **(c)** US scan shows a corresponding suspicious mass, but the spiculations are not as distinct as on the spot compression view. Invasive ductal carcinoma was pathologically confirmed.

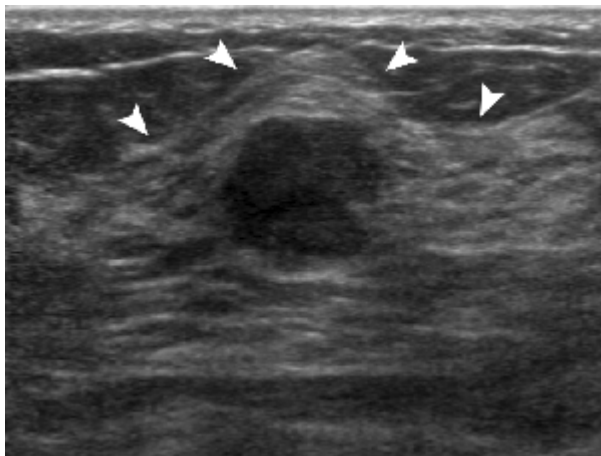
Spot compression is a valuable technique, but the radiologist should always be aware of some pitfalls. The spot compression view in the same projection as the standard mammographic view may produce only the same superimposition of structures and not differentiate a lesion from a summation shadow despite the increased pressure. It is important to obtain the spot view in the projection in which the finding is best seen or is displayed against fat to increase the likelihood of showing that the finding is a lesion (Fig 23) (14). As focal compression is applied, lesions can be rolled or squeezed out of the field of view, leading to the incorrect impression that they are not real. It is important to ensure that the area of concern is included in the field of view (8).



23a.



23b.



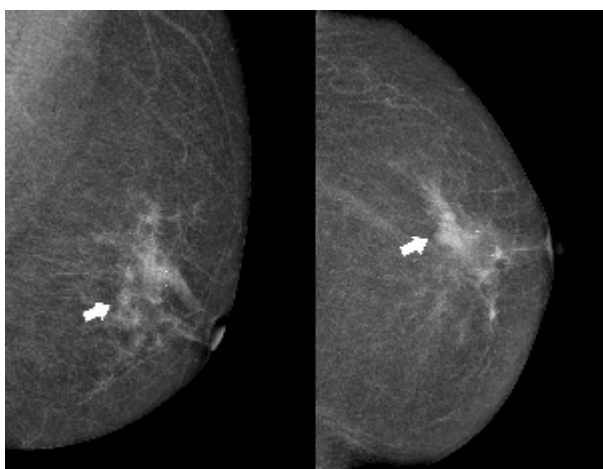
23c.

**Figure 23:** Pitfall of the spot compression view: the same superimposition of structures. **(a)** Mammographic views show a focal asymmetry (arrows) in the right upper outer aspect of the breast, which represents superimposition of structures. **(b)** No change in the asymmetry (arrow) or additional information is obtained from a spot compression. **(c)** US scan shows a benign-appearing mass surrounded by fibroglandular tissue (arrowheads). The mass was confirmed to be a fibroadenoma.

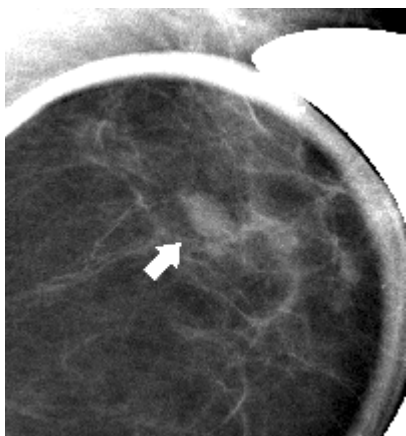
### US

When the anatomic location of a focal radiographic abnormality can be determined or a palpable asymmetric finding is correlated, targeted US is both indicated and valuable for either characterizing the abnormality or supporting an impression of focal

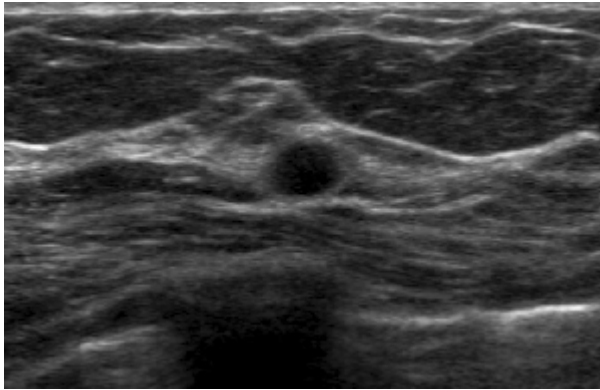
asymmetric tissue with no definable mass (Fig 24) (7). When the exact location of an abnormal finding cannot be ascertained, US may be applied to a larger area in searching for a presumed lesion. This approach may be successful but is less reliable because direct correlation with mammographic findings cannot be firmly established. Placement of a needle in the abnormality identified at US, with repeat mammography showing correlation to the US finding, may be necessary to establish concordance of findings. Skin markers are less reproducible but may be of value (7,8). When no logical inference as to the location of the density can be established mammographically or clinically, US is unreliable in evaluating the asymmetric finding.



24a.



24b.



24c.

**Figure 24:** Use of US to evaluate a focal asymmetry. (a) Mammographic views show a focal asymmetry (arrows) in the left breast. (b) Spot compression magnification view shows an oval circumscribed mass (arrow). (c) US scan depicts a benign cyst (BI-RADS category 2), which prompted routine follow-up.

### ***Magnetic Resonance (MR) Imaging***

The role of MR imaging for assessment of asymmetric breast findings has not yet been established (1). Brenner and Sickles (4,7) showed that the high sensitivity for breast cancer and relatively low specificity render MR imaging an unlikely tool for evaluating an asymmetric finding, given the low likelihood of malignancy among all types of asymmetry unless interval change can be documented (ie, a developing asymmetry). In contrast, Kuhl and Schnall et al (15,16) suggested that MR imaging, of which the negative predictive value is high enough to be used for problem solving, may represent a reasonable option for the work-up of a mammographic asymmetric finding. If the asymmetric finding is clearly identified at MR imaging, no architectural distortion is present, and the asymmetric finding demonstrates no contrast enhancement, its likelihood of being a cancer is low, and it is reasonable to assess this finding as benign or probably benign.

### **Conclusion**

Most of the asymmetric breast findings at mammography frequently encountered in our practice represent a benign superimposition of normal tissue or an island of fibroglandular tissue. However, it is possible that the finding represents cancer. The likelihood of cancer that has been reported varies, depending on the type of asymmetric finding. Detection of the asymmetric finding and application of the appropriate

classification criteria suggested by BI-RADS are fundamental; however, a clinical history should be also considered. Ancillary imaging studies to help interpret and manage asymmetric breast findings should be applied appropriately, and the radiologist should be aware of their pitfalls and pearls.

### References

1. Samardar P, de Paredes ES, Grimes MM, Wilson JD. Focal asymmetric densities seen at mammography: US and pathologic correlation. *RadioGraphics* 2002;22:19-33.
2. Kopans DB. Suspicious lesions and lesions with a high probability of malignancy. In: McAllister L, ed. *Breast imaging*. 3rd ed. Philadelphia, Pa: Lippincott Williams & Wilkins, 2007;513-553.
3. American College of Radiology. ACR BI-RADS: mammography. In: *ACR Breast Imaging Reporting and Data System, Breast Imaging Atlas*. 4th ed. Reston, Va: American College of Radiology, 2003.
4. Sickles EA. The spectrum of breast asymmetries: imaging features, work-up, management. *Radiol Clin North Am* 2007;45:765-771, v.
5. American College of Radiology. *Breast imaging reporting and data system*. In: *ACR Breast Imaging Reporting and Data System*. 3rd ed. Reston, Va: American College of Radiology, 1998.
6. Leung JW, Sickles EA. Developing asymmetry identified on mammography: correlation with imaging outcome and pathologic findings. *AJR Am J Roentgenol* 2007;188:667-675.
7. Brenner RJ. Asymmetric densities of the breast: strategies for imaging evaluation. *Semin Roentgenol* 2001;36:201-216.
8. Kopans DB. Image sequencing: problems and solutions in breast evaluation. In: McAllister L, ed. *Breast imaging*. 3rd ed. Philadelphia, Pa: Lippincott Williams & Wilkins, 2007;753-781.
9. Berg WA, Birdwell RL, Gombos EC, et al. Part IV: diagnoses. In: *Diagnostic imaging: breast*. Salt Lake City, Ut: Amirsys, 2006;6-9.
10. Kopans DB. Probably benign findings appropriately managed with short-interval follow-up. In: McAllister L, ed. *Breast imaging*. 3rd ed. Philadelphia, Pa: Lippincott Williams & Wilkins, 2007;505-511.
11. Kopans DB. Interpreting the mammogram. In: McAllister L, ed. *Breast imaging*. 3rd ed. Philadelphia, Pa: Lippincott Williams & Wilkins, 2007;365-479.

12. Kopans DB, Swann CA, White G, et al. Asymmetric breast tissue. *Radiology* 1989;171:639-643.
13. Berkowitz JE, Gatewood OM, Gayler BW. Equivocal mammographic findings: evaluation with spot compression. *Radiology* 1989;171:369-371.
14. Ikeda DM. Mammogram interpretation. In: Surrena H, ed. *Breast imaging: the requisites*. Philadelphia, Pa: Elsevier, 2004;24-59.
15. Kuhl CK. Current status of breast MR imaging. Part 2. Clinical applications. *Radiology* 2007;244:672-691.
16. Schnall M, Orel S. Breast MR imaging in the diagnostic setting. *Magn Reson Imaging Clin N Am* 2006;14:329-337, vi.

## Asymmetric Mammographic Findings Based on the Fourth Edition of BI-RADS: Types, Evaluation, and Management

*Ji Hyun Youk, MD, et al*

RadioGraphics 2008; e33 • Published online 10.1148/rg.e33 • Content Codes: BR MO

---

In contrast to a mass, which is a three-dimensional structure demonstrating convex outward borders and which is usually evident on two orthogonal views, according to BI-RADS (Fig 1), asymmetric findings lack the convex outward borders and the conspicuity typical of a mass (3,4).

If a potential mass is seen in only a single view at standard mammography, it should be called an “asymmetry” until its three-dimensionality is confirmed.

This asymmetric finding involves a greater volume of breast tissue over a significant portion of the breast (at least a quadrant), relative to the corresponding region in the contralateral breast, without any associated mass, suspicious calcifications, or architectural distortions (Fig 3).

Focal asymmetry is visible as a confined asymmetry with a similar shape on two views but does not fit the criteria of a mass: that is, it lacks convex outer borders and conspicuity (Fig 4). In contrast to global asymmetry, it occupies a volume of less than one quadrant of the breast and is of more concern.

Once such a potential abnormality is found, it is necessary to determine whether it is three-dimensionally real or just a projection artifact of superimposed normal structures. The tendency to rely on conventional projections only may be an obstacle to the proper evaluation of asymmetry. Although it can be inconvenient, it is better to have the patient return for additional evaluation than to make a management decision based on insufficient information.