



# Ankle Ligaments on MRI: Appearance of Normal and Injured Ligaments

Kiley D. Perrich<sup>1</sup>  
 Douglas W. Goodwin<sup>1</sup>  
 Paul J. Hecht<sup>2</sup>  
 Yvonne Cheung<sup>1</sup>

**OBJECTIVE.** The objective of our study was to provide a pictorial survey of MR images of ankle ligaments in various conditions from intact to disrupted.

**CONCLUSION.** MR images of ankle ligaments from a sample of patients with ankle pain or injury are presented and reviewed.

**E**very day in the United States, roughly 10,000 people will suffer an ankle injury, with most of these being sprains [1]. MRI can depict ligament injuries and has been used to differentiate ligament tears from other causes of ankle pain, such as fracture, osteochondral injury, or tendon injury. Appropriate treatment planning for ankle injury requires differentiation between the various types of ligament injury. This article provides an overview of the MRI features of normal and abnormal ligaments of the ankle (Appendix 1). Injured ligaments on MRI may appear disrupted, thickened, heterogeneous, or attenuated in signal intensity, and may be abnormal in contour. Fluid-sensitive sequences are often helpful in detecting injury.

Imaging was performed at our institution using our standard protocol (Table 1) on a 1.5-T scanner (Signa Horizon LX, GE Healthcare) with an extremity coil. Images used here were collected from patients referred for ankle MRI for ankle pain or for evaluation of injury from December 29, 2003 through August 10, 2007.

## Lateral Complex

The lateral collateral ligament complex (Figs. 1–4) is the most commonly injured group of ankle ligaments and is often associated with ligament injury elsewhere in the ankle. The lateral complex, comprising the anterior talofibular, calcaneofibular, and posterior talofibular ligaments, is adequately imaged with routine axial and coronal images [2–6]. Hyalinization of tissue in the an-

terolateral recess, a meniscoid lesion, may result from injury of the anterior talofibular ligament and can contribute to anterolateral impingement [7].

## Medial Complex and Deltoid Ligaments

Isolated medial collateral or deltoid ligament injuries (Figs. 1 and 5–9) are infrequent and are commonly associated with injury to other ligaments or malleolar fractures. The medial collateral ligament complex is further divided into superficial and deep layers. The deep ligaments have talar attachments and cross one joint, whereas the superficial ligaments have variable attachments and cross two joints. The three components that are most often visualized on MRI include the tibiospring and tibionavicular ligaments in the superficial layer and the posterior tibio-talar ligament of the deep layer [8].

## Syndesmosis

The syndesmotic ligaments include the anterior inferior tibiofibular ligament, the posterior inferior tibiofibular ligament, the inferior transverse tibiofibular ligament, and the inferior interosseous ligament or membrane [9] (Figs. 1 and 10–12). A syndesmotic ligament injury or “high ankle sprain” can be isolated or may occur in conjunction with injury of other ligament groups. It may also be associated with Weber B or C ankle fractures [9–12].

We have not included an image of the inferior transverse tibiofibular ligament because no such ligament injuries were encountered during the period of this study.

**Keywords:** ankle, ligaments, MRI

DOI:10.2214/AJR.08.2286

Received December 21, 2008; accepted after revision February 12, 2009.

<sup>1</sup>Department of Radiology, Dartmouth-Hitchcock Medical Center, One Medical Center Dr., Lebanon, NH 03756. Address correspondence to Y. Cheung (yvonne.cheung@hitchcock.org).

<sup>2</sup>Department of Orthopaedics, Dartmouth-Hitchcock Medical Center, Lebanon, NH.

## CME

This article is available for CME credit. See www.arrs.org for more information.

AJR 2009; 193:687–695

0361–803X/09/1933–687

© American Roentgen Ray Society

**TABLE 1: Routine MRI Protocol to Evaluate for Ligament Injury**

Sequence	Plane	Frequency-Selective Fat Saturation	TR	TE	Inversion Time (ms)	Section Thickness / Interval (mm)	Echo Train Length	Matrix
Spin-echo T1-weighted	Sagittal	No	400–700	10–20	—	4 / 1		256 × 256
STIR	Sagittal	No	4,000	50	150	4 / 1		256 × 256
Fast spin-echo proton density-weighted	Oblique axial <sup>a</sup>	Varies	2,000–3,000	15	—	3–4 / 1	5–6	512 × 512
Fast spin-echo proton density—and T2-weighted	Axial	Yes	3,500–6,000	80	—	4 / 1	5–6	256 × 256
Fast spin-echo proton density-weighted	Coronal	Yes	2,000–3,000	15	—	3–4 / 1	5–6	256 × 256

<sup>a</sup>45 degrees between coronal and sagittal planes.

### Spring Calcaneonavicular Ligament Complex

The plantar calcaneonavicular ligament is also known as the spring ligament complex (Figs. 1 and 13–15). The complex extends from the calcaneus to the tarsal navicular. A fibrocartilaginous portion of the ligament lies superficial to the talar head. The spring ligament consists of three components: the superomedial calcaneonavicular ligament, the medioplantar oblique calcaneonavicular ligament, and the inferoplantar longitudinal calcaneonavicular ligament [13, 14]. Of these, the superomedial calcaneonavicular ligament is most often involved in acute traumatic injury. Published studies of isolated spring ligament injuries are rare [15, 16]. Because of the proximity of the spring ligament to the posterior tibial tendon and its integral function in stabilizing the plantar arch, spring ligament injuries are often associated with posterior tibial tendon dysfunction [17].

### Summary

MRI provides a means of depicting ligament injuries and can be used to differentiate ligament tears from other causes of ankle pain and injury. In this article we have provided guidelines for the MRI differentiation of the various types of ligament injury.

### Acknowledgment

We thank Daniel Deneen for his assistance in preparing and editing this manuscript.

### References

- Holmer P, Sondergaard L, Konradsen L, Nielsen PT, Jorgensen LN. Epidemiology of sprains in the lateral ankle and foot. *Foot Ankle Int* 1994; 15:72–74
- Erickson SJ, Smith JW, Ruiz ME, et al. MR imaging of the lateral collateral ligament of the ankle. *AJR* 1991; 156:131–136
- Farooki S, Sokoloff RM, Theodorou DJ, et al. Visualization of ankle tendons and ligaments with MR imaging: influence of passive positioning. *Foot Ankle Int* 2002; 23:554–559
- Kreitner KF, Ferber A, Grebe P, Runkel M, Berger S, Thelen M. Injuries of the lateral collateral ligaments of the ankle: assessment with MR imaging. *Eur Radiol* 1999; 9:519–524
- Labovitz JM, Schweitzer ME, Larka UB, Solomon MG. Magnetic resonance imaging of ankle ligament injuries correlated with time. *J Am Podiatr Med Assoc* 1998; 88:387–393
- Lee SH, Jacobson J, Trudell D, Resnick D. Ligaments of the ankle: normal anatomy with MR arthrography. *J Comput Assist Tomogr* 1998; 22:807–813
- Robinson P, White LM, Salonen DC, Daniels TR, Ogilvie-Harris D. Anterolateral ankle impingement: MR arthrographic assessment of the anterolateral recess. *Radiology* 2001; 221:186–190
- Mengiardi B, Pfirrmann CWA, Vienne P, Hodler J, Zanetti M. Medial collateral ligament complex of the ankle: MR appearance in asymptomatic subjects. *Radiology* 2007; 242:817–824
- Bartonicek J. Anatomy of the tibiofibular syndesmosis and its clinical relevance. *Surg Radiol Anat* 2003; 25:379–386
- Brown KW, Morrison WB, Schweitzer ME, Parelada JA, Nothnagel H. MRI findings associated with distal tibiofibular syndesmosis injury. *AJR* 2004; 182:131–136
- Ebraheim NA, Lu J, Yang H, Mekhail AO, Yeasting RA. Radiographic and CT evaluation of tibiofibular syndesmosis diastasis: a cadaver study. *Foot Ankle Int* 1997; 18:693–698
- Morris JR, Lee J, Thordarson D, Terk MR, Brustein M. Magnetic resonance imaging of acute Maisonneuve fractures. *Foot Ankle Int* 1996; 17:259–263
- Mengiardi B, Zanetti M, Schottle PB, et al. Spring ligament complex: MR imaging—atomic correlation and findings in asymptomatic subjects. *Radiology* 2005; 237:242–249
- Taniguchi A, Tanaka Y, Takakura Y, Kadono K, Maeda M, Yamamoto H. Anatomy of the spring ligament. *J Bone Joint Surg Am* 2003; 85-A:2174–2178
- Chen JP, Allen AM. MR diagnosis of traumatic tear of the spring ligament in a pole vaulter. *Skeletal Radiol* 1997; 26:310–312
- Pathria MN, Rosenstein A, Bjorkengren AG, Gershuni D, Resnick D. Isolated dislocation of the tarsal navicular: a case report. *Foot Ankle* 1988; 9:146–149
- Anderson MW, Kaplan PA, Dussault RG, Hurwitz S. Association of posterior tibial tendon abnormalities with abnormal signal intensity in the sinus tarsi on MR imaging. *Skeletal Radiol* 2000; 29:514–519

## MRI of Ankle Ligaments

### APPENDIX I: Ankle Ligaments

#### Lateral complex

- Anterior talofibular ligament
- Posterior talofibular ligament
- Calcaneofibular ligament

#### Medial complex (deltoid)

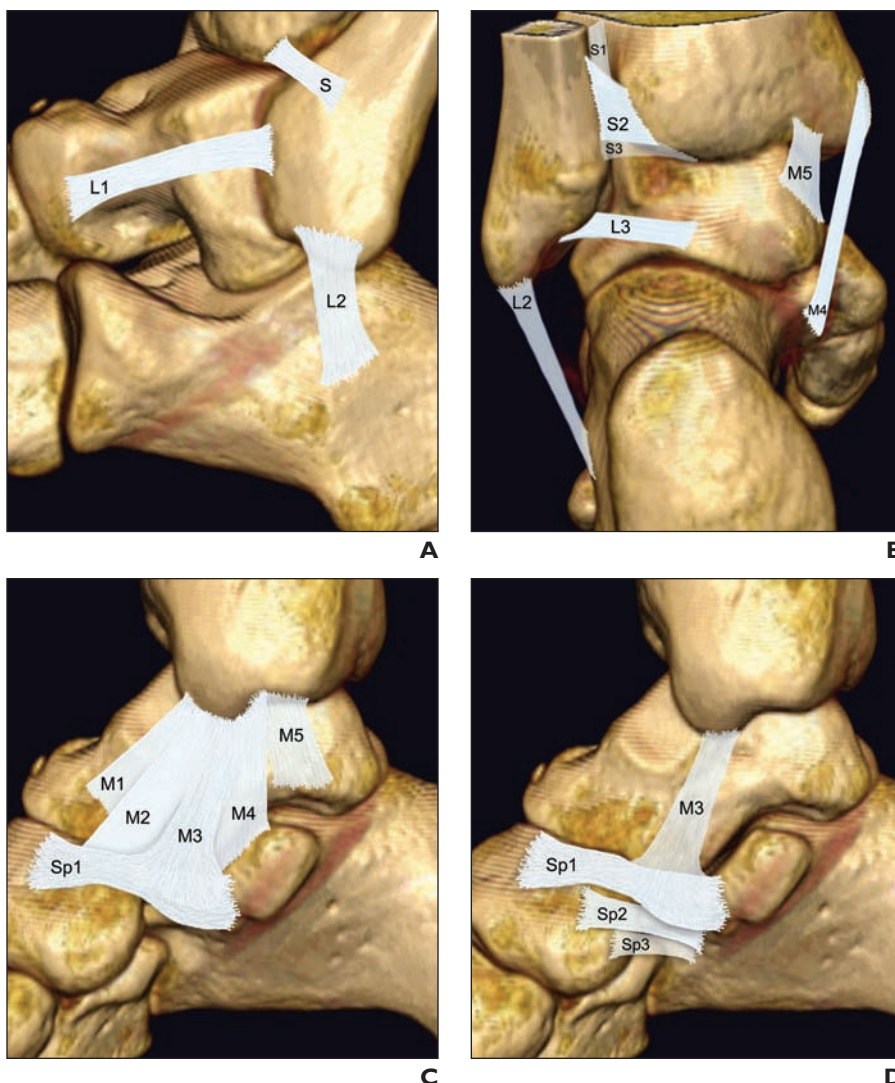
- Tibionavicular ligament
- Tibiospring ligament
- Tibiocalcaneal ligament
- Anterior tibiotalar ligament
- Posterior tibiotalar ligament

#### Ankle syndesmosis

- Anterior inferior tibiofibular ligament
- Posterior inferior tibiofibular ligament
- Inferior transverse ligament
- Distal interosseous ligament or membrane

#### Spring ligament complex (calcaneonavicular ligament)

- Superomedial calcaneonavicular ligament
- Medioplantar oblique calcaneonavicular ligament
- Inferoplantar longitudinal calcaneonavicular ligament



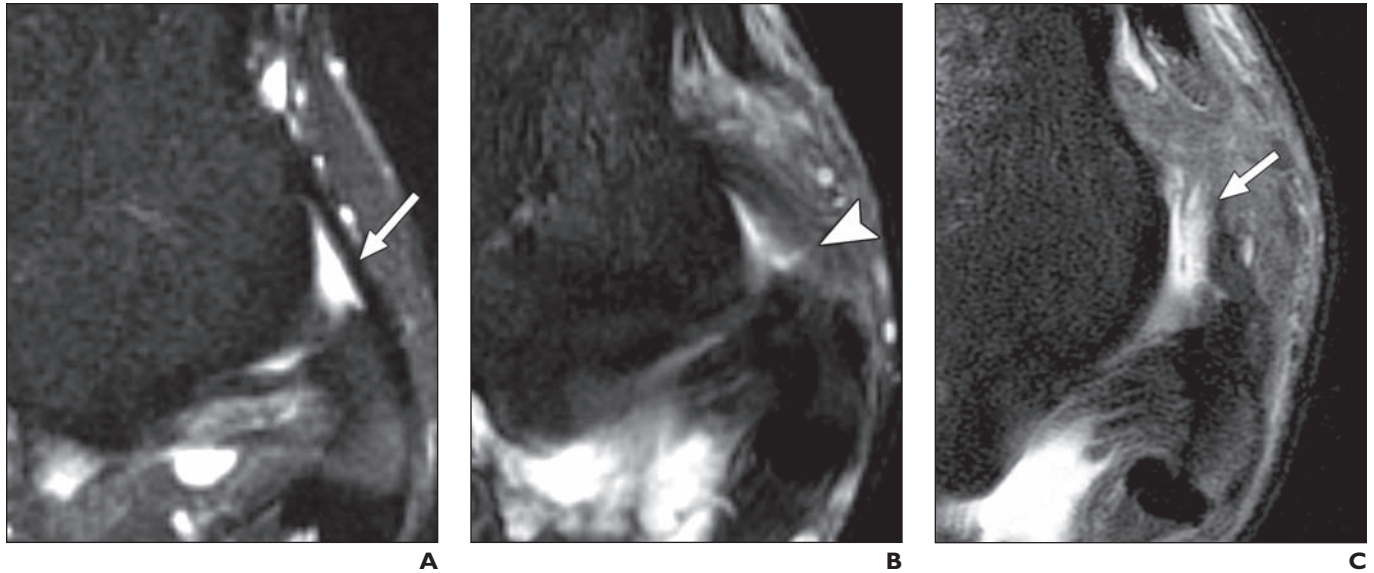
**Fig. 1**—Ankle ligaments. (See Appendix 1 for full ligament names.)

**A**, Ligaments visible laterally: anterior talofibular (L1), calcaneofibular (L2), anterior inferior tibiofibular (S) ligaments.

**B**, Ligaments visible posteriorly: interosseous ligament or membrane (S1), posterior inferior tibiofibular (S2), inferior transverse tibiofibular (S3), posterior talofibular (L3), tibiocalcaneal (M4), and posterior tibiotalar (M5) ligaments.

**C**, Ligaments visible medially: anterior tibiotalar (M1), tibionavicular (M2), tibiospring (M3), tibiocalcaneal (M4), posterior tibiotalar (M5), and superomedial calcaneonavicular (Sp1) ligaments.

**D**, Ligaments composing calcaneonavicular and spring ligament complex: superomedial calcaneonavicular (Sp1), medioplantar oblique calcaneonavicular (Sp2), and inferoplantar longitudinal calcaneonavicular (Sp3) ligaments. Tibiospring ligament (M3) belongs to superficial layer of medial complex and is included here to show its insertion to superomedial calcaneonavicular ligament.



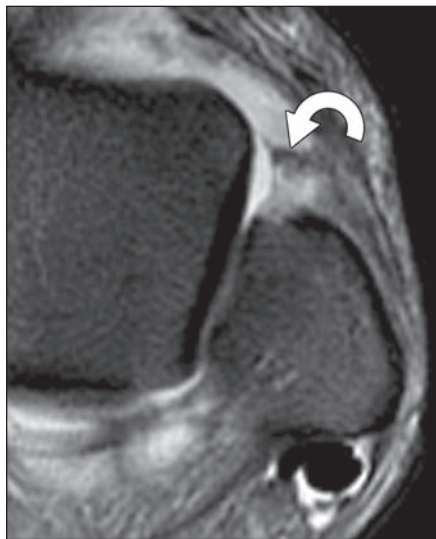
**Fig. 2**—Lateral complex: anterior talofibular ligament. Anterior talofibular ligament is weakest of lateral ligaments. It extends from anterolateral malleolar tip to talar neck, stabilizing talus.

**A**, 44-year-old woman with chronic ankle pain. Anterior talofibular ligament is well visualized on fluid-sensitive sequences such as this axial T2-weighted image. Uninjured ligament is of uniform thickness and low T1 and T2 signal intensity (*arrow*).

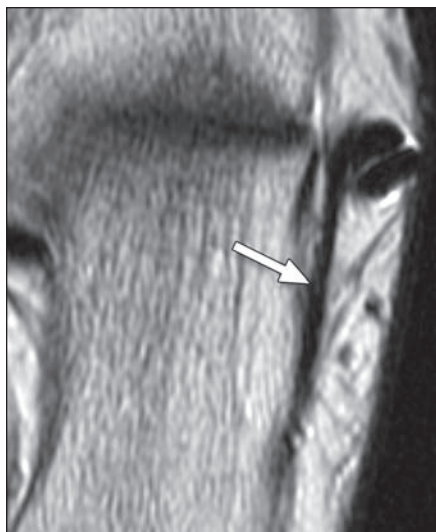
**B**, 17-year-old boy with pain and swelling and history of remote ankle injury. Partial tear of anterior talofibular ligament on axial T2-weighted image shows thickened ligament with increased internal signal (*arrowhead*).

**C**, 17-year-old boy with ankle pain after injury. Complete tear of anterior talofibular ligament on axial T2-weighted image shows discontinuous ligament surrounded by extensive fluid signal (*arrow*).

**D**, 19-year-old woman with continued ankle pain after sprain. Axial T2-weighted image shows nodular soft tissue occupying anterolateral gutter (*arrow*). Torn anterior talofibular ligament, seen in more distal image, is not included.



**D**



**A**

**Fig. 3**—Lateral complex: calcaneofibular ligament. Calcaneofibular ligament lies deep in relation to peroneal tendons and extends from lateral malleolar tip to trochlear eminence, stabilizing subtalar joint. Calcaneofibular is often partially imaged in coronal or axial planes; multiple images are often needed to visualize its entire course.

**A**, 31-year-old woman with suspected anterior tibial tendon tear. Oblique axial proton density-weighted image of intact calcaneofibular ligament (*arrow*) shows regular contour and homogeneously low signal.

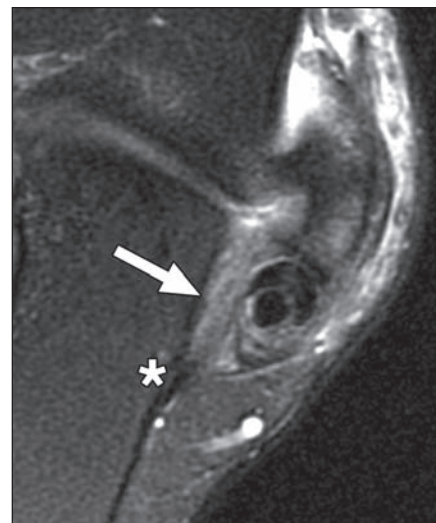
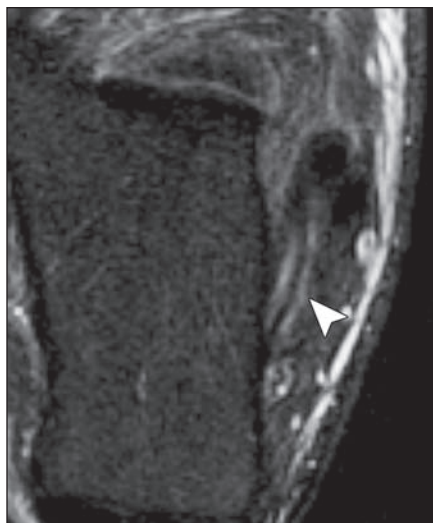(**Fig. 3** continues on next page)

## MRI of Ankle Ligaments

**Fig. 3 (continued)**—Lateral complex: calcaneofibular ligament. Calcaneofibular ligament lies deep in relation to peroneal tendons and extends from lateral malleolar tip to trochlear eminence, stabilizing subtalar joint. Calcaneofibular is often partially imaged in coronal or axial planes; multiple images are often needed to visualize its entire course.

**B**, 24-year-old man with Weber type B fracture of fibula. Oblique axial T2-weighted image of partial tear of calcaneofibular ligament shows fluid signal in ligament and mildly irregular contour (*arrowhead*).

**C**, 41-year-old woman with ankle trauma. Oblique axial T2-weighted image of complete tear of calcaneofibular ligament shows discontinuous ligament with adjacent fluid signal (*arrow*). Ligament at its calcaneal insertion (*asterisk*) is not disrupted.



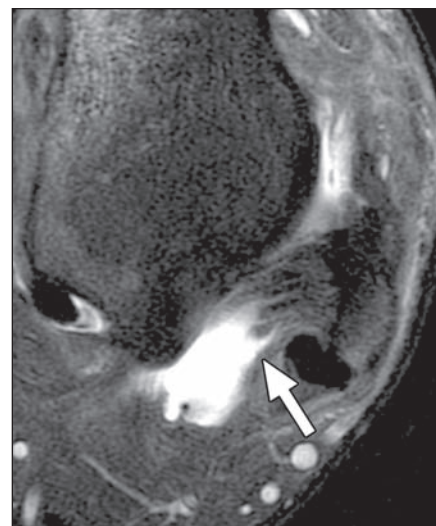
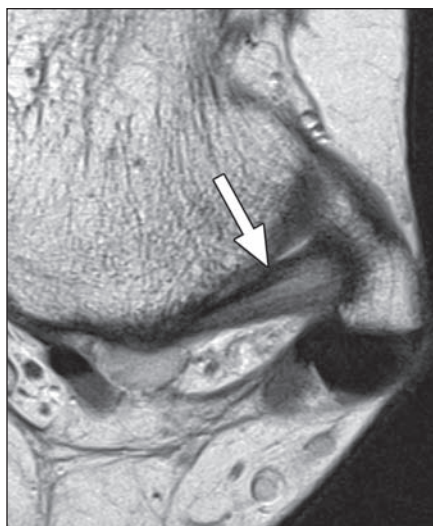
**B**

**C**

**Fig. 4**—Lateral complex: posterior talofibular ligament. Posterior talofibular is least frequently injured of three lateral complex ligaments, extending from posterior talus (lateral tubercle) to fibular malleolar fossa. Posterior talofibular often appears striated on MRI because of its fibrofatty composition [7].

**A**, 37-year-old man with medial ankle pain. Normal posterior talofibular ligament (*arrow*) has linear striations on this axial proton density-weighted image.

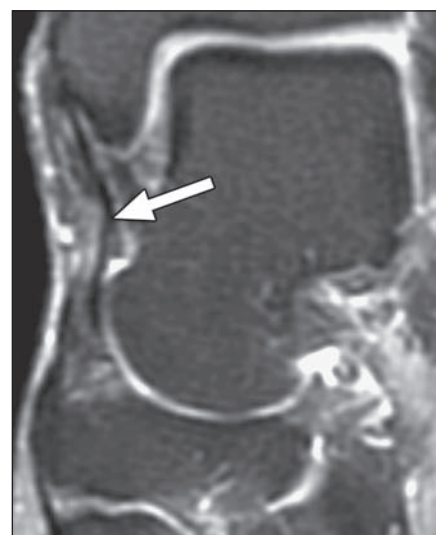
**B**, 17-year-old boy with ankle pain after injury. Complete tear of posterior talofibular ligament is seen as ligament defect on axial T2-weighted image. Torn ends of discontinuous ligament are surrounded by fluid signal (*arrow*).

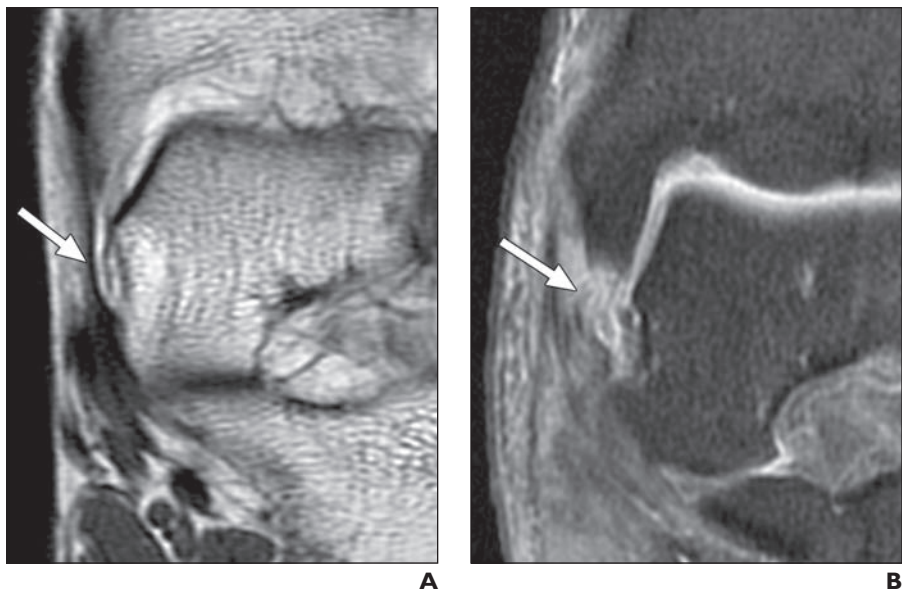


**A**

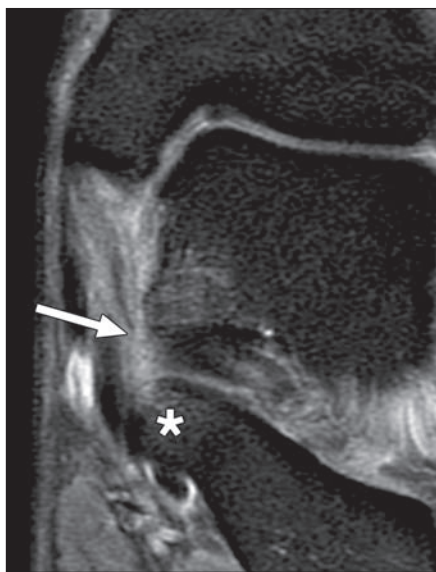
**B**

**Fig. 5**—Medial complex and deltoid: tibionavicular ligament. Tibionavicular ligament inserts onto navicular and is visible on only 55% of MR images of asymptomatic subjects. Because of its variable visualization, it is unreliable in assessing ligament injury. Coronal T2-weighted image in 73-year-old woman with tarsal tunnel syndrome and foot pain shows intact tibionavicular ligament (*arrow*).

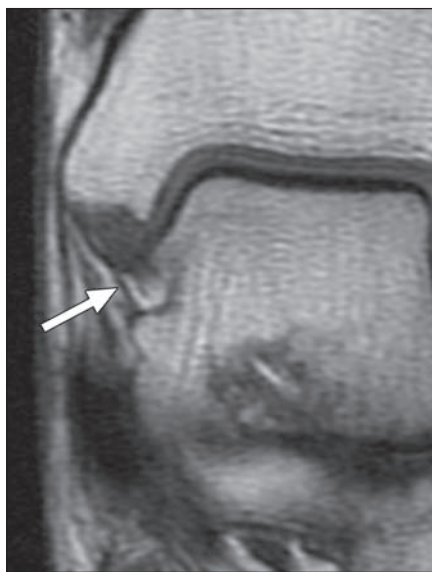




**Fig. 6**—Medial complex and deltoid: tibiospring ligament. Tibiospring ligament connects medial malleolar colliculus to superomedial spring ligament. **A**, 44-year-old woman with ankle pain. Coronal proton density-weighted image of intact tibiospring ligament shows its attachment to spring ligament (*arrow*). **B**, 20-year-old woman with Weber type B fracture. Complete tear of tibiospring ligament on coronal T2-weighted image shows discontinuous, irregular fibers (*arrow*).



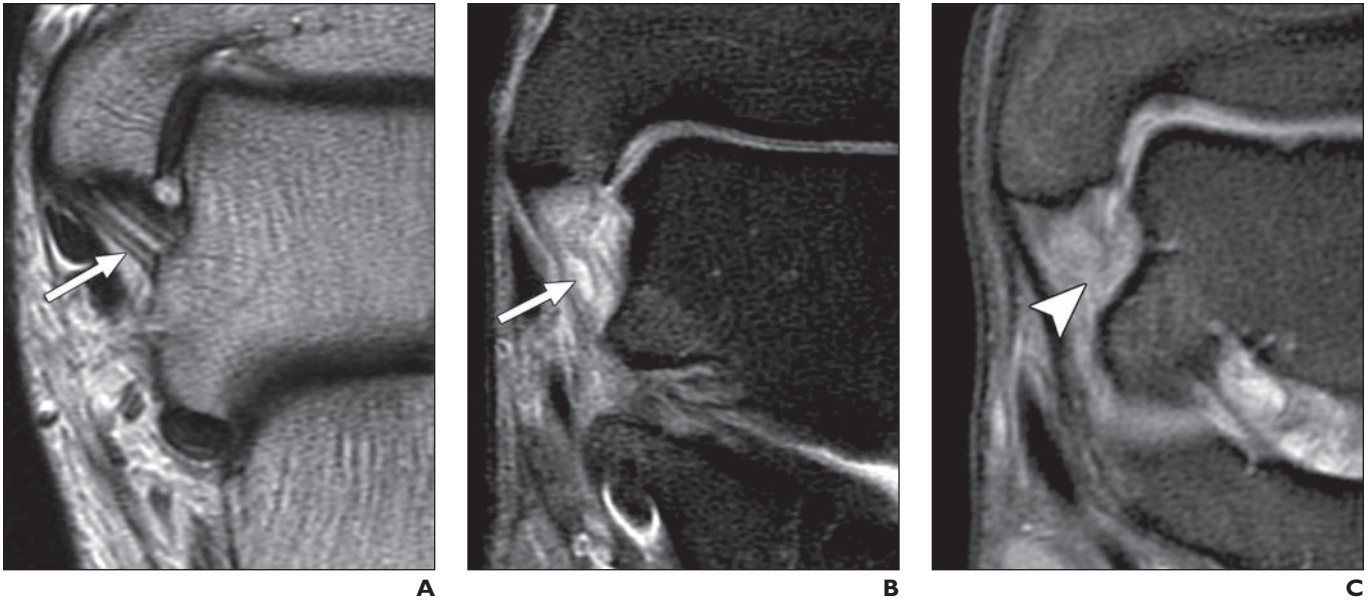
**Fig. 7**—Medial complex and deltoid: tibiocalcaneal ligament. Tibiocalcaneal connects medial malleolus to sustentaculum tali (*asterisk*). This ligament is visualized in 88% of asymptomatic subjects on MR images [13]. Coronal T2-weighted image in 29-year-old man with ankle pain shows complete tear and distal disruption of tibiocalcaneal ligament (*arrow*).



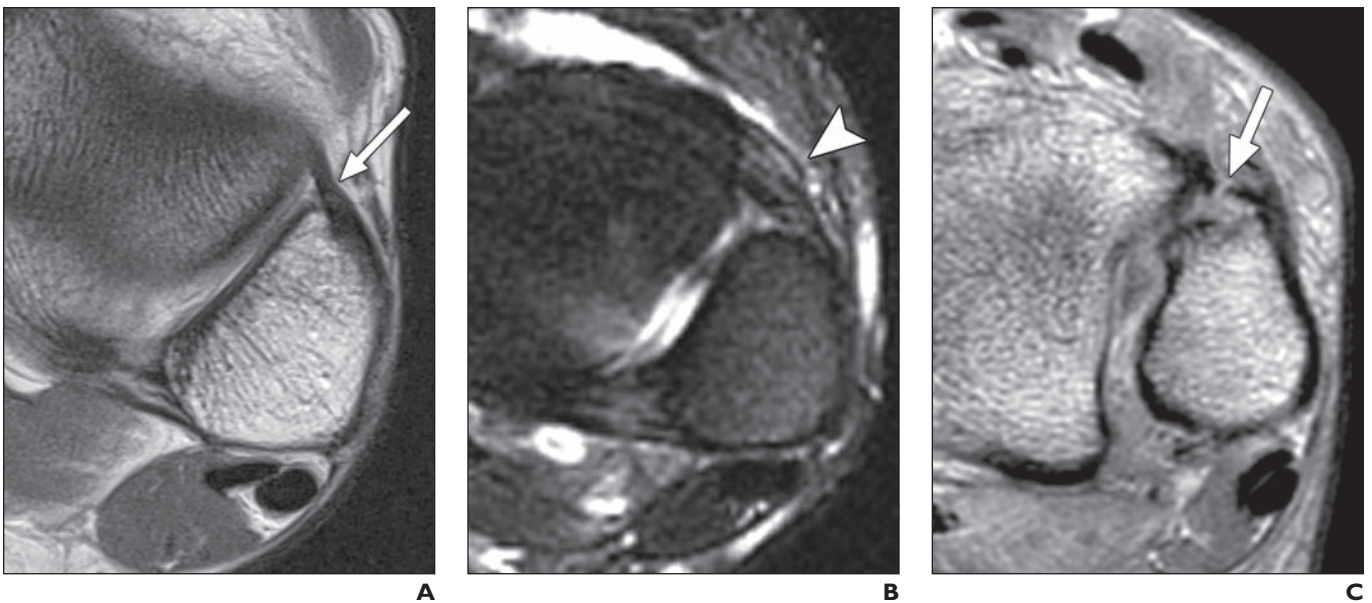
**Fig. 8**—Medial complex and deltoid: anterior tibiotalar ligament. Anterior tibiotalar ligament is thin and of uniformly low signal intensity on proton density-weighted images. It is inconsistently visualized on routine MRI studies. Its absence is not reliable indicator of injury. Coronal proton density-weighted image in 56-year-old woman with ankle and foot pain shows intact anterior tibiotalar ligament (*arrow*).

Downloaded from www.ajronline.org by 98.255.240.45 on 06/10/13 from IP address 98.255.240.45. Copyright ARRS. For personal use only; all rights reserved

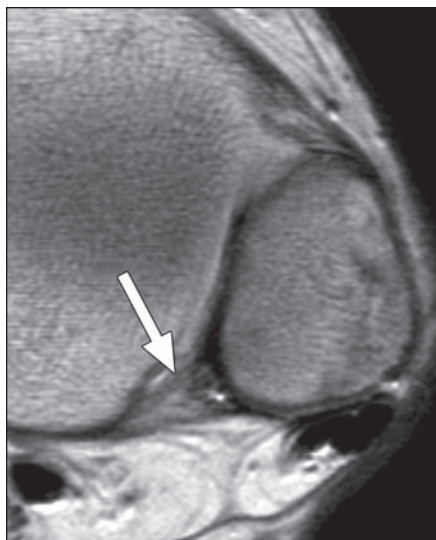
## MRI of Ankle Ligaments



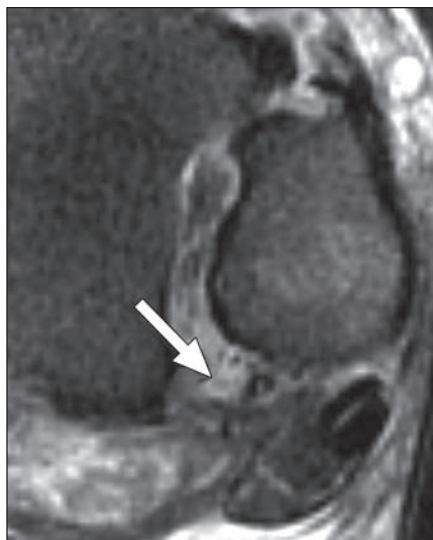**Fig. 9**—Medial complex and deltoid: posterior tibiotalar ligament. Posterior tibiotalar is thickest of medial ligaments with intervening fat separating its fascicles, often resulting in striated appearance in normal ligament. Fascicular disruption, irregularity, and loss of striation are indicators of injury.  
**A**, 49-year-old man with Achilles tendinopathy. Coronal T2-weighted image of intact posterior tibiotalar ligament shows continuous fibers and intervening fat between fascicles (*arrow*).  
**B**, 29-year-old man with ankle pain. Coronal T2-weighted image of partial tear of posterior tibiotalar ligament shows irregular contour and disrupted fibers with fluid signal near its talar attachment (*arrow*).  
**C**, 20-year-old man with persistent ankle pain after eversion injury. Coronal T2-weighted image shows complete disruption of posterior tibiotalar ligament and irregular contour of visible fibers, none of which appears attached at its talar insertion (*arrowhead*).



**Fig. 10**—Syndesmosis: anterior inferior tibiofibular ligament. Anterior inferior tibiofibular ligament extends from anterior tibial tubercle to fibular tubercle and is best visualized on axial images. Normal anterior inferior tibiofibular ligament may show fascicular appearance, which should not be confused with injury or tear.  
**A**, 43-year-old woman with ruptured plantar fascia. Intact anterior inferior tibiofibular ligament is low in signal intensity on axial proton density-weighted image (*arrow*).  
**B**, 19-year-old man with right-ankle pain after injury. Axial T2-weighted image of partial tear of anterior inferior tibiofibular ligament shows fluid signal in thickened, irregular ligament (*arrowhead*).  
**C**, 44-year-old man with high fibular fracture. Axial proton density-weighted image of complete tear of anterior inferior tibiofibular ligament shows discontinuous ligament (*arrow*).



A

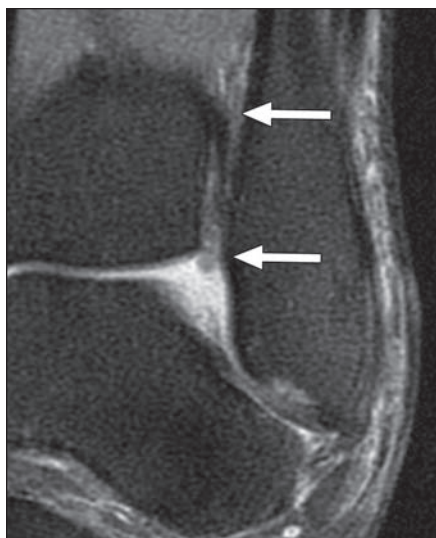


B

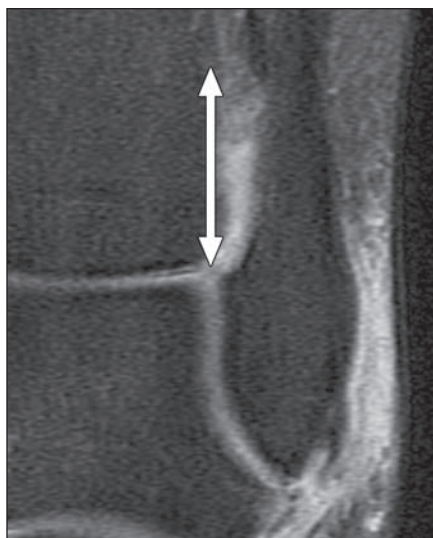
**Fig. 11**—Syndesmosis: posterior inferior tibiofibular ligament. Posterior inferior tibiofibular ligament extends from posterior tibial tubercle to posterior fibula. Most inferior fascicles (not shown) comprise inferior transverse ligament.

**A**, 17-year-old boy with avascular necrosis and steroid therapy. Intact posterior inferior tibiofibular ligament (*arrow*) is seen on axial proton density-weighted image.

**B**, 44-year-old man with high fibular fracture. Complete tear of posterior inferior tibiofibular ligament on axial T2-weighted image is seen as discontinuous ligament (*arrow*).



A

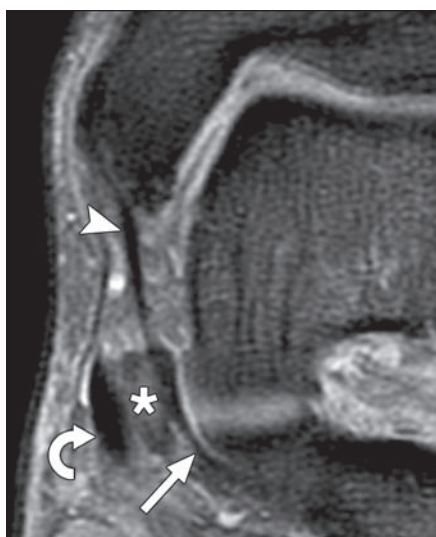


B

**Fig. 12**—Syndesmosis: distal interosseous ligament or membrane. Interosseous ligament is inferiormost portion of interosseous membrane. It connects medial fibula to lateral tibia. Its inferior margin lies adjacent to tibiofibular recess and is lined with synovium [11]. Recess extends superiorly 5 mm from joint line on MR images of healthy subjects [12]. When fluid signal extends more than 12 mm into tibiofibular recess, syndesmotic injury should be considered [12].

**A**, 14-year-old girl with ankle pain. Intact interosseous ligament or membrane is seen on coronal T2-weighted image. Note absence of fluid in tibiofibular recess (*arrows*).

**B**, 44-year-old woman with ankle pain. Torn interosseous ligament or membrane is seen on coronal T2-weighted image. Fluid signal extends into tibiotalar recess 13 mm superior to joint line (*arrow*), indicating high likelihood of interosseous ligament or membrane tear.



A

**Fig. 13**—Spring ligament complex: superomedial calcaneonavicular ligament. Superomedial calcaneonavicular ligament originates from sustentaculum tali of calcaneus and inserts onto superomedial tarsal navicular. It lies deep in relation to posterior tibial tendon (PTT). Superficial surface of superomedial calcaneonavicular ligament is composed of fibrocartilaginous gliding zone. Of three components of spring ligament complex, superomedial calcaneonavicular ligament is most likely to be injured. PTT dysfunction is often associated with spring ligament injury.

**A**, 69-year-old man with high fibular fracture and pain. Coronal T2-weighted image shows intact superomedial calcaneonavicular ligament (*straight arrow*) and adjacent PTT (*curved arrow*). Normal tibiospring ligament is also visible (*arrowhead*). Asterisk indicates fibrocartilaginous gliding zone.

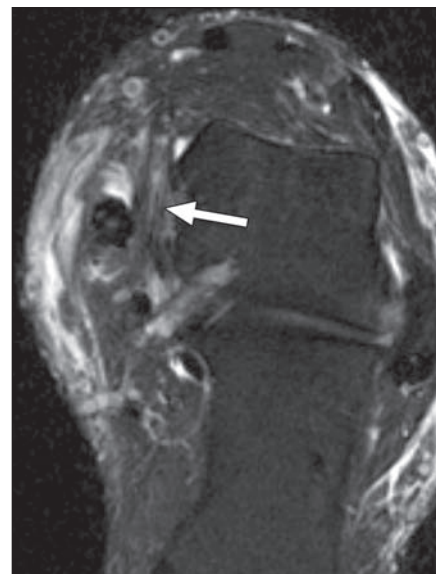
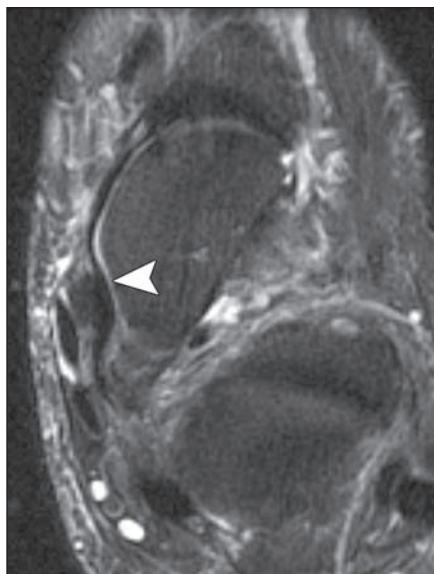
(**Fig. 13 continues on next page**)

## MRI of Ankle Ligaments

**Fig. 13 (continued)**—Spring ligament complex: superomedial calcaneonavicular ligament. Superomedial calcaneonavicular ligament originates from sustentaculum tali of calcaneus and inserts onto superomedial tarsal navicular. It lies deep in relation to posterior tibial tendon (PTT). Superficial surface of superomedial calcaneonavicular ligament is composed of fibrocartilaginous gliding zone. Of three components of spring ligament complex, superomedial calcaneonavicular ligament is most likely to be injured. PTT dysfunction is often associated with spring ligament injury.

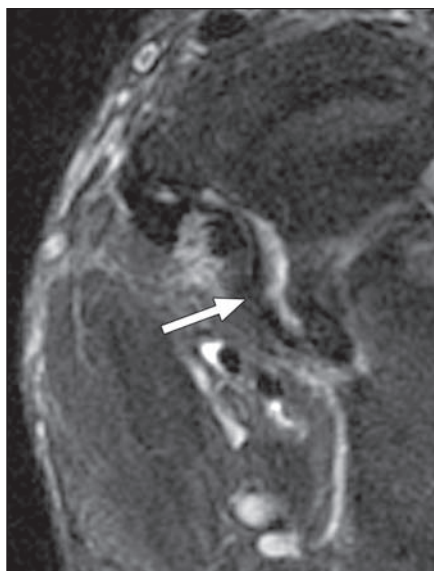
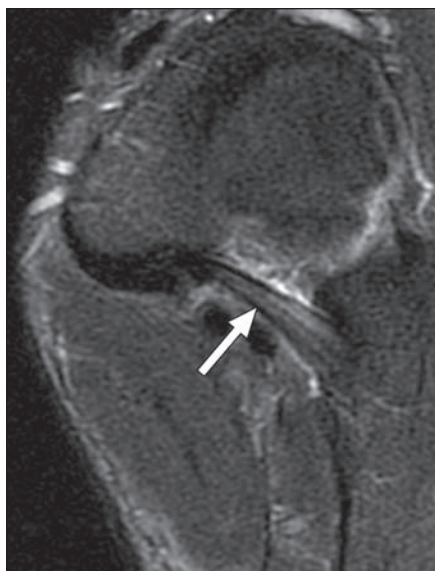**B**, 69-year-old man with ankle pain and talar osteochondral injury. Axial T2-weighted image shows normal contour and homogeneously low signal in superomedial calcaneonavicular ligament (*arrowhead*).

**C**, 50-year-old man with foot and ankle pain. Oblique axial T2-weighted image shows partial tear of superomedial calcaneonavicular ligament (*arrow*). Abnormally thickened, irregular superomedial calcaneonavicular ligament contains bright fluid signal.



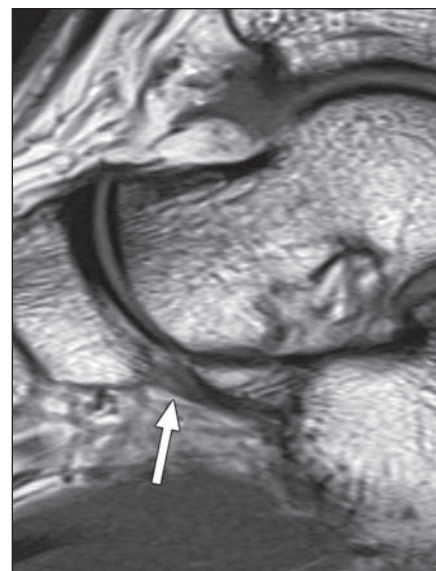
**B**

**C**



**A**

**B**



**Fig. 14**—Spring ligament complex: medioplantar oblique calcaneonavicular ligament. Medioplantar oblique calcaneonavicular ligament extends from medial portion of navicular bone to calcaneal coronoid fossa and is best visualized in axial plane.

**A**, 21-year-old man with chronic foot pain. Normal striated appearance of uninjured medioplantar oblique calcaneonavicular ligament is shown on axial T2-weighted image (*arrow*).

**B**, 50-year-old man with foot and ankle pain. Complete tear of medioplantar oblique calcaneonavicular ligament is shown on axial T2-weighted image. Note irregular, wavy contour of ligament and interruption at its calcaneal attachment (*arrow*).

**Fig. 15**—Spring ligament complex: inferoplantar longitudinal calcaneonavicular ligament. Inferoplantar calcaneonavicular ligament lies anterior to medioplantar oblique calcaneonavicular ligament, extending from inferior navicular bone to calcaneal coronoid fossa. It is usually thickest of three components of spring ligaments and is seen in 91% of asymptomatic subjects [13]. Sagittal T1-weighted image shows intact inferoplantar longitudinal calcaneonavicular ligament (*arrow*) in 20-year-old man with ankle pain and suspected osteochondral injury.

### FOR YOUR INFORMATION

This article is available for CME credit. See [www.arrs.org](http://www.arrs.org) for more information.